
Reconstruction with Extended Vertical Lower Trapezius Island Myocutaneous Flap for Total Glossectomy

Wei Liang CHEN¹, Fang Song QIU², Ke WANG¹, Zhi Quan HUANG¹, Zhao Hui YANG¹, Jin Song LI¹

Objective: To explore effective reconstruction of the defects of tongue following total glossectomy with extended vertical lower trapezius island myocutaneous flap.

Methods: Eleven patients with advanced squamous cell carcinoma of the tongue were treated with glossectomy and repaired with extended vertical lower trapezius island myocutaneous flap based with the transverse cervical artery for the defect of tongue. The size of the skin paddle varied from 8 cm * 6 cm to 9 cm * 7 cm.

Results: No major flap failure and no shoulder dysfunction occurred. All of the patients had uneventful postoperative courses and began to intake food perorally 8 to 15 days postoperatively. The patients were followed for 8 to 26 months (average 20.6 months). The function of the tongue for speech and swallowing were satisfactory.

Conclusion: The extended vertical lower trapezius island myocutaneous flap was suitable for reconstructing total tongue defects following ablation of advanced tongue cancer.

Key words: tongue cancer, trapezius myocutaneous flap, reconstruction

Although surgical treatment for malignant tumour of the tongue has advanced remarkably over the last two decades because of progress in reconstructive surgery, it is still a challenge to reconstruct a total tongue. In 1979, Demergasso and Piazza¹ described the trapezius myocutaneous flap in which the transverse cervical artery (TCA) and paraspinous attachment of the trapezius were left intact. In 1980, Baek et al² first described the lower trapezius island myocutaneous flap (LTIMF) for reconstructing cutaneous defects or subcutaneous augmentation of the face. In 2000, Tan and Tan³ report-

ed the vascular anatomy and clinical use of the extended LTIMF based solely on the dorsal scapular artery system. In 2004, Ugurlu et al⁴ proposed that the extended vertical trapezius myocutaneous flap based solely on the TCA could be used as a salvage procedure for previous failed flap procedures and tumour recurrence. Since that flap is not an island flap, a second operation is necessary. Chen and co-workers^{5,6} believed that the extended vertical LTIMF is suitable for reconstructing cranio-maxillofacial soft tissue defects and is preferred as a salvage procedure for oral and maxillofacial soft tissue defects after salvage surgery for patients with recurrent oral squamous cell carcinoma. This article puts forth a new approach to tongue reconstruction using an extended vertical LTIMF.

Materials and Methods

The subjects of this study consisted of 11 patients with advanced squamous cell carcinoma of the tongue that

1 Department of Oral and Maxillofacial Surgery, Second Affiliated Hospital of Sun Yat-sen University, Guangzhou, P.R. China.

2 Department of Oral and Maxillofacial Surgery, The Jiangmen Central Hospital, Jiangmen City, Guangdong Province, P.R. China.

Corresponding author: Dr Wei Liang CHEN, Department of Oral and Maxillofacial Surgery, the Second Affiliated Hospital of Sun Yat-Sen University, 107 Yanjiang Road, Guangzhou 510120, P. R. China. Tel: 86-020-81332429. E-mail:drchen@vip.163.com

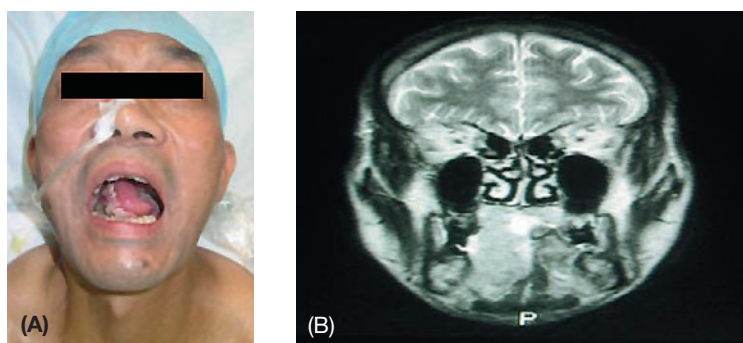


Fig 1 A 56-year-old man who presented with a squamous cell carcinoma of the right tongue in stage T4. (A) An ulcerous tumour measuring 6 cm * 4 cm was seen in the right lingual body and the mouth floor. (B) MRI showed the tumour involving most of the tongue and the mouth floor.

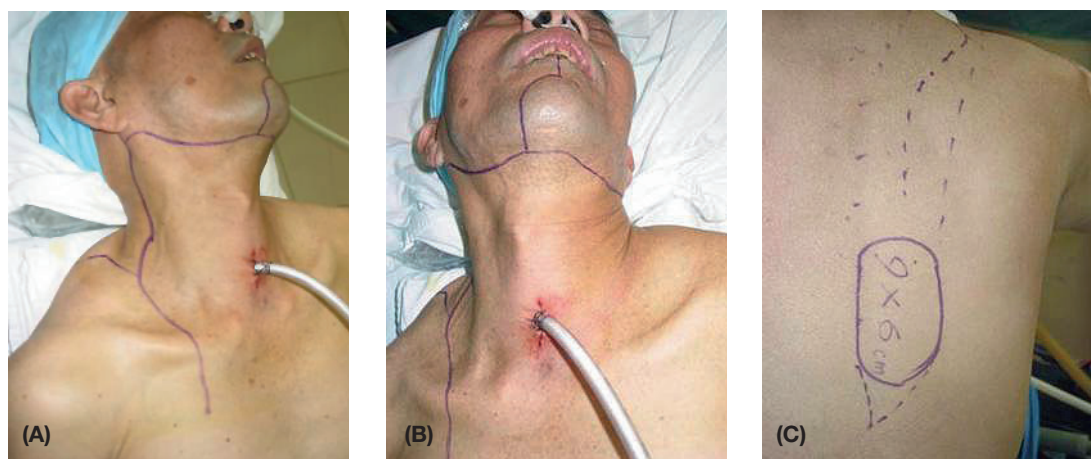


Fig 2 Design of the operation. (A) Design of glossectomy with the ipsilateral radical neck dissection and (B) the contralateral supraomohyoid neck dissection. (C) Design of the extended vertical LTIMF with a skin paddle measuring 9.0 cm * 6.0 cm.

had undergone total glossectomy and reconstruction by the extended vertical LTIMF between October 2004 and January 2007. The patients were 46 to 69 years of age, with a mean of 52.8 years and consisted of eight men and three women. The tumour stage was T4 in all patients (Fig 1). Ipsilateral radical neck dissection (Fig 2A), contralateral supraomohyoid neck dissection (Fig 2B), excision of total tongue, and a partial mandibulectomy were performed in all cases. An extended vertical LTIMF with a flap skin paddle measuring 8–9 cm in

length and 6–7 cm in width (average 8.5 cm * 6.5 cm) was used to reconstruct total lingual defects following radical surgery (Fig 2C). All the patients were pathohistologically diagnosed as squamous cell carcinomas with ipsilateral regional lymph node metastasis and the margins of the specimens were tumour free. All the patients received radiotherapy (60 Gy) for the primary site and neck postoperatively. Four patients with pathological findings of multiple neck lymph nodes metastasis even received adjuvant chemotherapy.

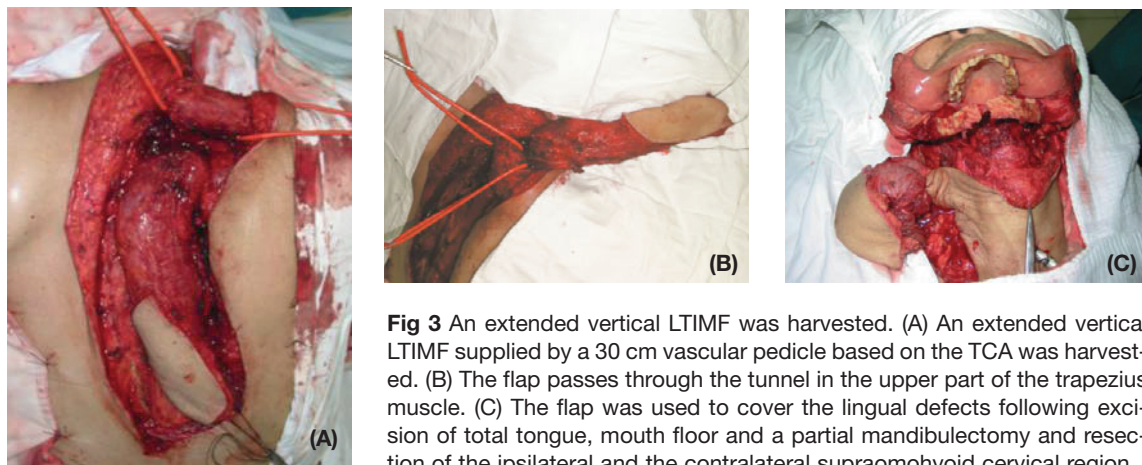


Fig 3 An extended vertical LTIMF was harvested. (A) An extended vertical LTIMF supplied by a 30 cm vascular pedicle based on the TCA was harvested. (B) The flap passes through the tunnel in the upper part of the trapezius muscle. (C) The flap was used to cover the lingual defects following excision of total tongue, mouth floor and a partial mandibulectomy and resection of the ipsilateral and the contralateral supraomohyoid cervical region.

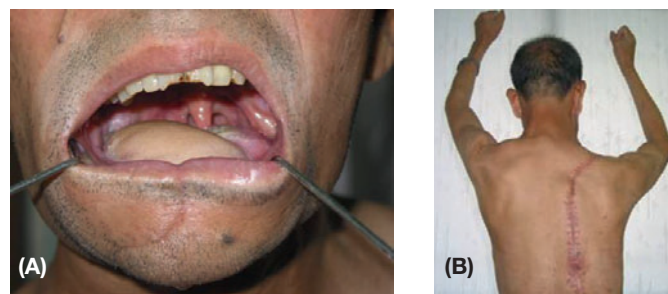


Fig 4 The total lingual defect was reconstructed by an extended vertical LTIMF 12 months postoperatively. (A) The lingual contours were satisfactory. (B) No disabilities with regard to shoulder motion.

Surgical technique

The main blood supply of the trapezius muscle and overlying skin is from superficial and deep descending branches of the TCA. Doppler mapping was used to identify the TCA preoperatively in all patients. The extended vertical LTIMF was elevated with the patient in the lateral prone position. The skin paddle of the flap, based mainly on the fasciocutaneous extension beyond the trapezius muscle at right angles to the lateral margin of the trapezius muscle, was designed to follow the course of the TCA by centring the long axis of the flap between the vertebral column and the medial border of the scapula. The medial border of the flap was marked

0.5 cm lateral to the spinal processes. The width of the flap was approximately 7 cm and the lateral border was marked accordingly. The pivot point of the flap was the level of the thyrocervical trunk in the lower neck. The pedicle length was determined according to the distance between the pivot point and the defect. The flap measured 6–7 cm in width and 28–38 cm in length. Flap elevation began from the midpoint of the flap and proceeded from medial to lateral. After identifying the trapezius muscle, the medial vertebral insertions were incised. Caudal cranial dissection of the trapezius muscle with the overlying dorsal skin was easily carried out beneath the trapezius muscle. Care should be taken to identify the TCA and vein, which was easily visualized lying on the

deep fascia on the undersurface of the trapezius muscle and was incorporated within the flap. After including the TCA, the lateral border of the flap was incised. While elevating the flap, the underlying latissimus dorsi and rhomboid muscle were seen. At the line of transition between the rhomboid major and minor, the dorsal scapular artery, lying laterally to the TCA, was ligated. This released the flap, allowing it to be dissected cranially. The cranial dissection ended at the level of the scapular spine (the level of thoracic vertebra 11-12), while preserving the upper parts of the trapezius muscle and the lateral attachment of the trapezius to the scapular spine and acromion to prevent shoulder droop and weakness. A tunnel was made in the upper part of the trapezius muscle; the flap could be dissected further to the point of entrance of the TCA based on the thyrocervical trunk to increase the length of the flap (Fig 3A). The caudal end of the flap was then extended from 10 to 13 cm beyond the caudal end of the trapezius muscle, making the distal lateral half of the flap random and producing a well-vascularised, thin, long island flap. It could pass through the tunnel in the upper part of the trapezius muscle and neck region and finally be used to cover the lingual defects (Figs 3B and 3C). The donor area was closed directly.

Results

No major flap failure occurred, but one patient experienced marginal necrosis of the flap. The donor site healed well in all the patients. The lingual contours were satisfactory after repair (Fig 4A). All the patients had uneventful postoperative courses and began to intake food perorally 8 to 15 days postoperatively. There were no disabilities with regard to shoulder movements (Fig 4B). The patients were followed for 8 to 26 months (average 20.6 months). The function of the tongue for speech and swallowing were satisfactory. Four patients with extracapsular lymph node spread developed local recurrence; three of them are still alive with the recurrence, but one has died.

Discussion

Netterville and Wood⁷ described a surgical technique for repair with use of an extended lower trapezius flap based on the dorsal scapular artery. Tan and Tan³ thought that the extended LTIMF is based solely on the dorsal scapular artery system and is a useful flap for head and neck reconstruction. Ugurlu et al⁴ observed that, although the dorsal scapular artery is divided, the extended vertical trapezius myocutaneous flap can be elevated safely with a total length of 38 cm without arterial insufficiency.

This flap is not an island flap; the skin and vessels within can allow a longer flap to be prepared with a well-perfused distal end, so no major flap failure occurs. However, this requires a pedicle division as a second stage several weeks postoperatively⁴. Urken et al⁸ reported three major flap failures and three minor flap failures in 45 cases of head and neck reconstruction using the LTIMF based exclusively on the TCA. In our series of extended vertical LTIMF based solely on the TCA for reconstructing total tongue defects following radical surgery, no major flap failure occurred. One patient with minor flap failure was treated conservatively, and the wound healed secondarily. The minor flap failure resulted from tension on the pedicle secondary to extreme head and neck movement. Four patients developed local recurrence and one of them died of the local recurrence or metastasis, since all of the patients were stage T4. As the shoulder function is often weakened in patients undergoing radical neck dissection after division of the accessory nerve, we preserved the upper parts of the trapezius muscle and rhomboid muscles. This measurement helped to minimise functional shoulder disturbances and these complications were within acceptable limits. The extended vertical LTIMF had several advantages. The pedicle did not need to be separated postoperatively. The long thin musculocutaneous pedicle allowed for easy transfer of the island flap, which could be tunnelled into a defect in the oral regions. Treatment with the vascular pedicle could be performed in the same field with the radical neck dissection, suturing of the donor site, and excision of the tumours simultaneously when the patient was placed in the semi-lateral position. However, the surgical procedure was difficult and not feasible in situations when contralateral surgery was required. The flaps also easily filled the defect created by the neck dissection and cover the vessels of the neck preventing damage to the vessels. The extended vertical LTIMF has the potential for a wider acceptance because of the low donor-site morbidity, and it is well hidden. The pectoralis major flap is an often-used versatile myocutaneous flap for the immediate reconstruction of wide defects resulting after resection of malignant tumours of the head and neck. However, it is usually associated with a high incidence of complications, such as dehiscence, infection, haematoma, seroma, partial flap failure, total flap failure, fistula, and donor site complications⁹. We believed that the pectoralis major myocutaneous pedicled flap was too large and bulky compared with the extended vertical LTIMF. The extended vertical LTIMF was more suitable for reconstruction of the total lingual defects. On the other hand, the development of an adenocarcinoma in accidentally displaced breast tissue of the pec-

toralis major flap was reported¹⁰. Besides, the extended vertical LTIMF was preferred in female patients when a myocutaneous flap is not ideal. In patients undergoing irradiation or chemotherapy, the extended vertical LTIMF could be performed safely, provided that the vascular bundle is present. The extended vertical LTIMF could not be used in patients undergoing radical neck dissection in which the TCA would be damaged. The TCA is anatomically variable and the accompanying vein is relatively thin in some cases, which increased the risk of venous congestion. For the successful utilization of trapezius myocutaneous flaps, it is very important to consider the vascular anatomy of the trapezius and its variation. A preoperative Doppler scan was very important for patients undergoing the extended vertical LTIMF.

References

1. Demergasso F, Piazza MV. Trapezius myocutaneous flap in reconstructive surgery for head and neck cancer: an original technique. *Am J Surg* 1979;138:533–536.
2. Baek SM, Biller HF, Krespi YP, Lawson W. The lower trapezius island myocutaneous flap. *Ann Plast Surg* 1980;5:108–114.
3. Tan KC, Tan BK. Extended lower trapezius island myocutaneous flap: a fasciomyocutaneous flap based on the dorsal scapular artery. *Plast Reconstr Surg* 2000;105:1758–1763.
4. Ugurlu K, Ozcelik D, Hüthüt I, Yildiz K, Kilinc L, Bas L. Extended vertical trapezius myocutaneous flap in head and neck reconstruction as a salvage procedure. *Plast Reconstr Surg* 2004;114:339–350.
5. Chen WL, Deng YF, Peng GG, Li JS, Yang ZH, Bai ZB, Huang ZQ, Wang JG, Zhang B. Extended vertical lower trapezius Island myocutaneous flap for reconstruction of cranio-maxillofacial defects. *Int J Oral Maxillofac Surg* 2007;36:165–170.
6. Chen WL, Li J, Yang Z, Huang Z, Wang J, Zhang B. Extended vertical lower trapezius island myocutaneous flap in reconstruction of oral and maxillofacial defects after salvage surgery for recurrent oral carcinoma. *J Oral Maxillofac Surg* 2007;65:205–211.
7. Nettekville JL, Wood DE. The lower trapezius flap. Vascular anatomy and surgical technique. *Arch Otolaryngol Head Neck Surg* 1991;117:73–76.
8. Urken ML, Naidu RK, Lawson W, Biller HF. The lower trapezius island musculocutaneous flap revisited. Report of 45 cases and a unifying concept of the vascular supply. *Arch Otolaryngol Head Neck Surg* 1991;117:502–511.
9. Liu R, Gullane P, Brown D, Irish J. Pectoralis major myocutaneous pedicled flap in head and neck reconstruction: retrospective review of indications and results in 244 consecutive cases at the Toronto General Hospital. *J Otolaryngol* 2001;30:34–40.
10. Depprich RA, Handschel JG, Braunstein S, Kubler NR. Breast carcinoma in a pectoralis major myocutaneous flap used for reconstruction of the oral cavity: a case report and review of the literature. *Oral Oncol Extra* 2005;41:238–241.