

---

# Growth of the Mandible after Condylar Reconstruction by Autogenous Coronoid Process Graft in Goats

Song Song ZHU<sup>1</sup>, Jing HU<sup>2</sup>, Na LI<sup>1</sup>, Da Zhang WANG<sup>2</sup>

**Objective:** *To investigate the effect of condylar reconstruction by autogenous coronoid process graft on mandibular growth.*

**Methods:** *Eighteen growing goats were randomly divided into group A (n = 10) and group B (n = 8). Each animal underwent right condyle removal and was treated by coronoid process graft. Three-dimensional computerised tomography was performed at different intervals. Animals in group A were used for mandibular measurements at 48 weeks postoperatively. Animals in group B were sacrificed at 24 and 48 weeks postoperatively for histological observation.*

**Results:** *No difference was found in ramus height, mandibular height, and mandibular length between the two sides. The neocondylar size increased significantly, whereas there was a significant reduction of ramus width on the operated side. A well-organised fibrocartilage was seen at the neocondylar surface over time.*

**Conclusion:** *This study suggests that a neocondyle reconstructed by autogenous coronoid process has the potential to grow under temporomandibular joint functional stimuli. Therefore, this technique may serve as an alternative method for condylar reconstruction in growing individuals.*

**Key words:** *temporomandibular joint, mandibular condyle, reconstruction, coronoid process, growth*

Mandibular condyle takes a crucial role in directing the growth pattern of the mandible, and condylar damage during childhood results in severe functional and cosmetic impairment<sup>1</sup>. Costochondral graft is the most recognised method for temporomandibular joint (TMJ) reconstruction in paediatric patients because of its potential for growth<sup>2,3</sup>. However, problems still remain,

such as inevitable donor site morbidity and unpredictable growth<sup>4,5</sup>.

A few surgeons have reported the use of autogenous coronoid process for TMJ reconstruction since it often needs to be resected and discharged in some cases, especially in those patients with joint ankylosis<sup>6-8</sup>. Our previous study on adult goats also showed that the grafted coronoid process could gradually remodel to a neocondyle with functional shape and structure under the mechanical stimuli of the TMJ site<sup>9</sup>, but it is unknown whether the mandible would continue to grow in young individuals after coronoid process transplantation.

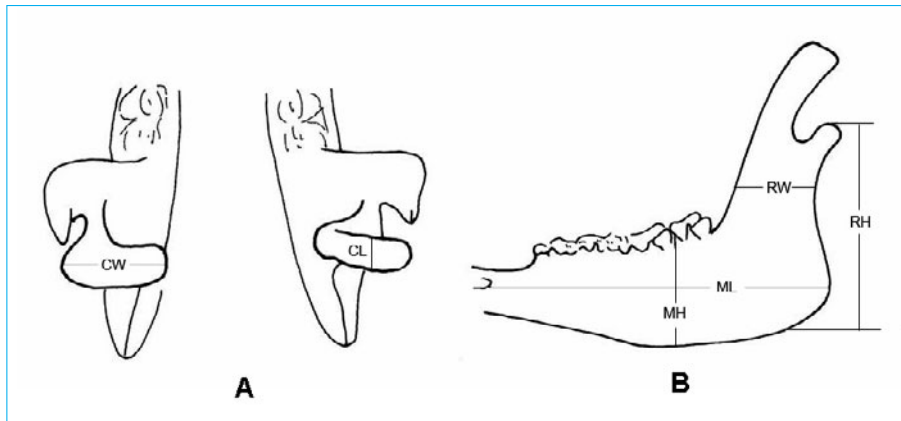
In the present study, we hypothesised that mandibular growth would not be disturbed following the condylar reconstruction by autogenous coronoid process graft. To test this, the effects of condylar reconstruction by auto-

---

1 The State Key Laboratory of Oral Diseases, Sichuan University, Chengdu, P.R. China.

2 Department of Oral and Maxillofacial Surgery, West China School of Stomatology, Sichuan University, Chengdu, P.R. China.

**Corresponding author:** Dr Jing HU, Department of Oral and Maxillofacial Surgery, West China School of Stomatology, Sichuan University, Chengdu 610041, P.R. China. Tel: 86-28-85502334. E-mail: drhu@vip.sohu.com



**Fig 1** Measurements of mandibular samples: (A) condylar width (CW) and condylar length (CL); (B) ramus height (RH), ramus width (RW), mandibular length (ML) and mandibular height (MH).

genous coronoid process on mandibular growth and its histological basis were evaluated.

### Materials and Methods

Eighteen male goats at 3 months of age were used in this study. The animal research protocol was reviewed and approved by the Animal Care and Use Committee at the university. According to the method described in our previous study<sup>9</sup>, a right condylar defect was created with preservation of articular disc, and reconstructed by ipsilateral coronoid process graft. The left intact condyles served as controls.

All animals received identical surgery and were randomly divided into group A ( $n = 10$ ) and group B ( $n = 8$ ). Group A animals received three-dimensional computerised tomography (CT) scanning (Somatom Sensation 16, Siemens, Erlangen, Germany) at 0, 4, 12, 24, and 48 weeks postoperatively. After sacrifice at 48 weeks after operation, their mandibles were prepared for growth evaluation. In group B, four randomly chosen animals were killed at 24 weeks and at 48 weeks after operation. Their TMJ samples were harvested and processed for histological examinations.

#### Measurement of mandibular growth

The mandibular halves from group A were separated and excised en bloc with surrounding soft tissue. Six parameters were selected and measured for assessment on the hemimandibles growth (Figs 1A and 1B).

1. The condylar width (CW): the transverse distance of the condyle from the most medial point to the most lateral point.

2. The condylar length (CL): the posteroanterior distance of the condyle from the most posterior point to the most anterior point.
3. The ramus height (RH): the distance from the most superior point of the condyle to the angle of the mandible; this was made perpendicular to the mandibular plane.
4. The ramus width (RW): distance from the anterior to the posterior border at the occlusal plane.
5. The mandibular length (ML): the distance from the posterior rim of the mental foramen to the posterior edge of the mandibular angle.
6. The mandibular body height (MH): the vertical distance between the inferior border of the mandible and the highest point of the alveolar ridge between the first and second molar.

#### Statistics

In group A, Wilcoxon matched-pair signed rank tests in SPSS software Version 11.5 (SPSS Inc, Chicago, IL) were performed to compare differences of mandibular growth between operated and unoperated sides. Probability levels of 0.05 or less were considered to indicate statistical significance.

#### Histology

In group B animals, bilateral TMJs samples were harvested and fixed in 10% neutral buffered formalin, decalcified in 0.5mol/l ethylenediaminetetraacetic acid. Paraffin sections (5  $\mu\text{m}$  thickness) were cut parallel to the sagittal plane. The slides were stained with haematoxylin and eosin (HE), Masson's trichrome, or (and) toluidine blue.

## Results

### Clinical examinations

All animals tolerated the experiment well and no signs of infection or other complications were noted during or after the operations. None of the animals showed mid-line deviation or obvious difficulty with mastication. Weight increased steadily in all growing animals. The animal weight at sacrifice corresponded to that of the adult weight, which confirmed that they had all attained maturity.

### Three-dimensional CT images

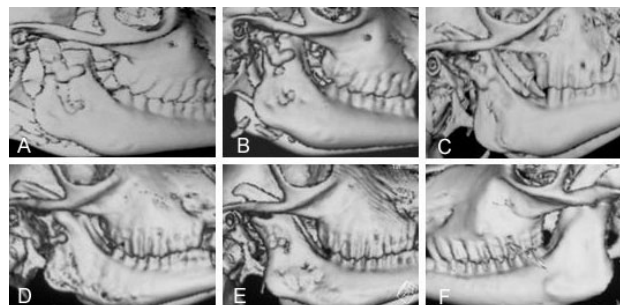
Immediately after operation, the grafted coronoid process was noted to articulate well with the glenoid fossa (Fig 2A). The grafts remained well attached to the ramus in their original positions at 4 weeks after operation, but a certain bony absorption of the graft was found. Partial reformation of the coronoid process was seen at the resected sites (Fig 2B). No further bone resorption was seen on the grafts at 12 weeks after operation. The grafts seemed to remodel to a neocondyle. The newly formed coronoid process was observed. It has an almost normal appearance with a somewhat backward shift (Fig 2C). At 24 weeks after operation, the head of bony graft became round and smooth and more like an articular head (Fig 2D). At 48 weeks, the neocondyle regenerated from the grafted coronoid process was indistinguishable from the normal one (Figs 2E and 2F).

### Mandibular growth

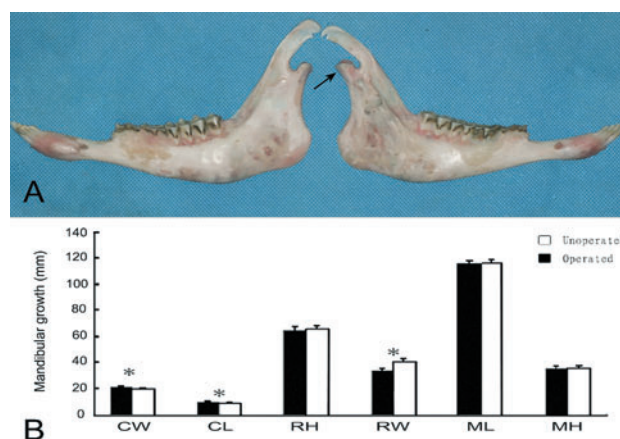
In the animals from group A, an increase in the condylar height and width and a decrease in the ramus width were found on the operated side, whereas there was no significant difference in the ramus height, the mandibular length, and the mandibular body height between the two sides (Figs 3A and 3B).

### Histology

At 24 weeks after operation, a neocondyle with a round and convex surface in the anteroposterior direction was seen and the fibrous layer was arranged irregularly (Fig 4A). Toluidine blue staining visualised a discontinuity in cartilage layer of joint surface (Fig 4B). At 48 weeks after operation, the neocondyle exhibited a smooth articular head and a continuous cartilaginous layer. The cellular structures resemble the normal histological appearances (Figs 4D and 4E). Masson's trichrome staining showed the presence of collagen for bone and cartilage,



**Fig 2** Serial three-dimensional images of the mandible: (A) immediately after operation; (B) 4 weeks after operation; (C) 12 weeks after operation; (D) 24 weeks after operation; (E) 48 weeks after operation; (F) the left normal condyle.



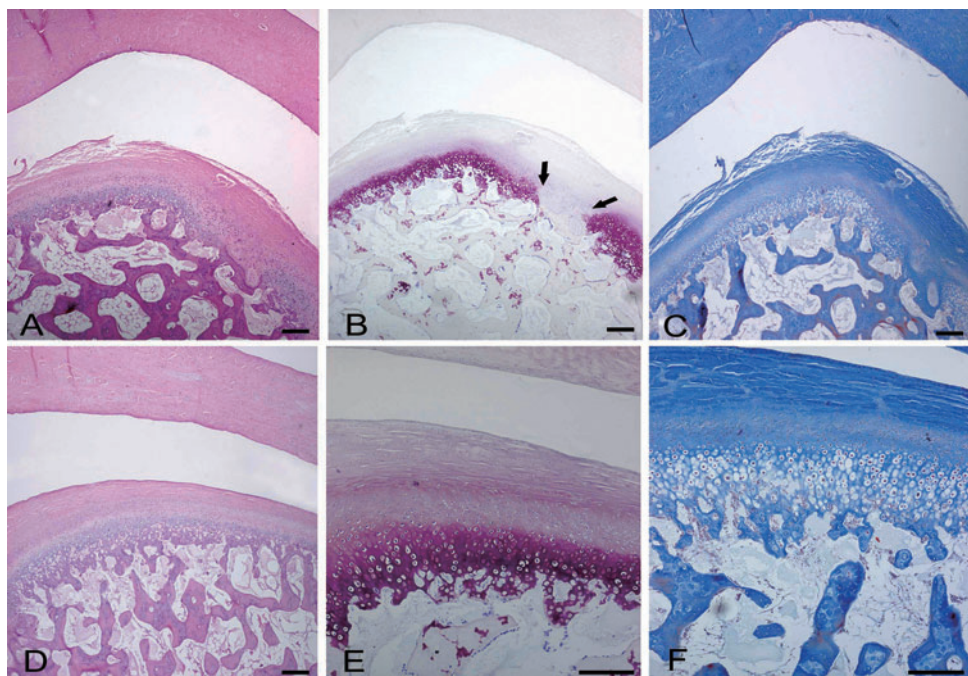
**Fig 3** Measurements of mandibular growth. (A) The hemimandibles at 48 weeks after operation: left, unoperated side; right, operated side (the regenerated coronoid process and arrow showing the neocondyle formed by autogenous coronoid process). (B) Comparison of the mandibles between two sides. Data are represented as mean plus/minus standard deviation. (\*  $p < 0.05$ , based on the Wilcoxon test)

which indicated that endochondral ossification was active in the neocondyle (Figs 4C and 4F).

## Discussion

Previous studies showed that autogenous coronoid process can be used as a good substitute for condyle reconstruction<sup>6-9</sup>, but there are no data about its effects on the subsequent growth of the mandible. The current study showed that the neocondyle reconstructed by autogenous coronoid process has the potential to grow under functional stimuli of the TMJ.

According to the measurements for mandibular growth, no significant differences were found between



**Fig 4** Histological sections of the mandibular condyle stained by HE (left), toluidine blue (middle), and Masson's trichrome (right): (A, B, C) 24 weeks after operation (arrows showing the damaged cartilage layer); (D, E, F) 48 weeks after operation. Scale bars: 200  $\mu$ m.

two sides in the ramus height, mandibular length and mandibular height. The restoration of the ramus height was of great importance for mandibular growth. Although partial spontaneous regeneration of the resected condyle has been reported in growing monkeys, the original height of the mandibular ramus was not recovered and open bite was noted in both studies due to the loss of posterior vertical dimension. In this study, midline deviation was not found in any animal, which suggests that the grafted coronoid process can take the role of growing site in young animals. A valid explanation for this is the functional matrix theories described by Moss, who believes that mandibular growth is promoted by functional stimuli in the TMJ<sup>10</sup>.

The other three parameters, however, were found to be different between two sides. The decrease in ramus width was probably due to extensive damage to the ramus in operation and a decreased growth stimulus resulting from an alteration in function<sup>11</sup>. In addition, enlargement of the articular head of the neocondyle was found in this study. This finding is consistent with previous studies<sup>9,12-14</sup>. It is partially explained by the neocondyle withstanding a different array of forces from the normal condyle due to lack of lubrication of articular fluid and buffer of articular cavity<sup>15,16</sup>.

Many investigations have confirmed the importance of condylar cartilage in mandibular growth<sup>17,18</sup>. Therefore, a cartilaginous component, such as a costochondral

graft, is recommended by many surgeons when dealing with condylar damage in children. However, mandibular growth after costal cartilage transplantation is unpredictable<sup>19</sup>. On the other hand, there is substantial experimental and clinical evidence to support the point of view that restoration of biomechanical structures and subsequent normal TMJ function, rather than growth centre transplantation such as cartilage, is responsible for the continued growth of mandible<sup>10,20,21</sup>. These reports raised questions about the role of the mandibular cartilage in mandibular growth. In the present study, the reoccurrence of the articular cartilage indicated that the cartilaginous component graft was not required for continued mandibular growth. The cells producing the articular cartilage at the condylar head most likely developed from undifferentiated mesenchymal cells in the surrounding periosteum, and differentiated slowly to the fibrocartilage in the area compressed by functional forces<sup>22</sup>. However, this does not imply that mandibular growth can occur in the absence of articular cartilage, because the target cells of various growth hormone and cytokines are located in the articular cartilage, especially those undifferentiated mesenchymal cells in proliferative layers<sup>23-25</sup>. As a matter of fact, both actions, the functional stimuli or articular cartilage, were indispensable and not mutually exclusive during mandibular growth, although the functional stimuli are considered as the primary force for the restoration of articular cartilage.



Additionally, excessive growth of the autogenous grafts was not observed in this animal study. The growth characteristics of primary cartilages, including costal cartilage, are controlled greatly by intrinsic and genetic factors<sup>13</sup>. This probably explains why mandibular deviation resulting from overgrowth on the operated side was often found when using costochondral grafts to replace condyle in paediatric patients. In the present study, the TMJ area appeared to provide a suitable environment for adaptive remodelling of the grafted coronoid process. The newly formed fibrocartilage covering the head of neocondyle has nearly the same histological structure as the normal one, and its growth characteristics were similar to a secondary cartilage whose growth is influenced by biomechanical environment<sup>4</sup>.

Another interesting finding is the regeneration of the coronoid process, which is consistent with our previous study<sup>9</sup>. This finding may be relative to the strong distraction force from temporal muscle and was supported by the post-mortem observation in which the temporal muscle reattached firmly and extensively to the surface of the regenerated coronoid process.

The current study suggests that a neocondyle with a very similar shape and histological structure to a normal condyle could be achieved by coronoid process graft, and it has the potential to grow under the functional stimuli of the TMJ site. Therefore, the autogenous coronoid process can be considered as an alternative method for TMJ reconstruction in growing individuals.

## Acknowledgements

This study was supported by a grant from the Science and Technology Bureau of Sichuan Province (project proposal No. 05SG022-019-3).

## References

- Cavaliere CM, Buchman SR. Mandibular distraction in the absence of an ascending ramus and condyle. *J Craniofac Surg* 2002; 13:527–532.
- Saeed NR, Kent JN. A retrospective study of the costochondral graft in TMJ reconstruction. *Int J Oral Maxillofac Surg* 2003;32:606–609.
- Wolford LM, Cottrell DA, Henry C. Sternoclavicular grafts for temporomandibular joint reconstruction. *J Oral Maxillofac Surg* 1994; 52:119–128.
- MacIntosh RB. The use of autogenous tissues for temporomandibular joint reconstruction. *J Oral Maxillofac Surg* 2000;58:63–69.
- Skouteris CA, Sotereanos GC. Donor site morbidity following harvesting of autogenous rib grafts. *J Oral Maxillofac Surg* 1989; 47:808–812.
- Hong Y, Gu X, Feng X, Wang Y. Modified coronoid process grafts combined with sagittal split osteotomy for treatment of bilateral temporomandibular joint ankylosis. *J Oral Maxillofac Surg* 2002; 60: 11–18.
- He ZQ. Clinical uses of coronoid process transplantation in the temporomandibular arthroplasty. *Zhong Hua Kou Qiang Yi Xue Za Zhi* 1987;22:35–37 (in Chinese).
- Hong M. Coronoid process grafting in treatment of temporomandibular ankylosis. *Zhong Hua Yi Xue Za Zhi* 1982;62:37–39 (in Chinese).
- Zhu SS, Hu J, Li N, Zhou HX, Luo E. Autogenous coronoid process as a new donor source for reconstruction of mandibular condyle: an experimental study on goats. *Oral Surg Oral Med Oral Pathol Oral Radiol Endod* 2006;101:572–580.
- Moss ML. The functional matrix concept and its relationship to temporomandibular-joint dysfunction and treatment. *Dent Clin North Am* 1983;27:445–455.
- Sorensen DC, Laskin DM. Facial growth after condylectomy or osteotomy in the mandibular ramus. *J Oral Surg* 1975;33:746–756.
- Stucki-McCormick SU, Fox RM, Mizrahi RD. Reconstruction of a neocondyle using transport distraction osteogenesis. *Semin Orthod* 1999;5:59–63.
- Peltomäki T, Vähätalo K, Rönning O. The effect of a unilateral costochondral graft on the growth of the marmoset mandible. *J Oral Maxillofac Surg* 2002;60:1307–1314.
- Zhu S, Hu J, Li J, Ying B. Reconstruction of mandibular condyle by transport distraction osteogenesis: experimental study in rhesus monkey. *J Oral Maxillofac Surg* 2006;64:1487–1492.
- Turner CH. Three rules for bone adaptation to mechanical stimuli. *Bone* 1998;23:399–407.
- Carter DR, Van Der Meulen MC, Beaupré GS. Mechanical factors in bone growth and development. *Bone* 1996;18(Suppl):5S–10S.
- Habib H, Hatta T, Udagawa J, Zhang L, Yoshimura Y, Otani H. Fetal jaw movement affects condylar cartilage development. *J Dent Res* 2005;84:474–479.
- Tang GH, Rabie AB. Runx2 regulates endochondral ossification in condyle during mandibular advancement. *J Dent Res* 2005;84: 166–171.
- Peltomäki T. Histologic structure of human costochondral junction. *Plast Reconstr Surg* 1994;94:585–588.
- Marciani RD, Gonty AA, White DK, Traurig HH. A preliminary study of reconstruction of the monkey temporomandibular joint with autogenous tissues. *J Oral Maxillofac Surg* 1996;54:191–199.
- Ellis III E, Schneiderman ED, Carlson DS. Growth of the mandible after replacement of the mandibular condyle: an experimental investigation in *Macaca mulatta*. *J Oral Maxillofac Surg* 2002;60:1461–1470.
- Moffett Jr BC, Johnson LC, McCabe JB, Askew HC. Articular remodeling in the adult human temporomandibular joint. *Am J Anat* 1964;115:119–41.
- Bibb CA, Pullinger AG, Baldioceda F. The relationship of undifferentiated mesenchymal cells to TMJ articular tissue thickness. *J Dent Res* 1992;71:1816–1821.
- Kaneyama K, Segami N, Sato J, Nishimura M, Yoshimura H. Expression of osteoprotegerin in synovial tissue and degradation of articular cartilage: comparison with arthroscopic findings of temporomandibular joint disorders. *Oral Surg Oral Med Oral Pathol Oral Radiol Endod* 2003;96:258–262.
- Delatte M, Von den Hoff JW, Kuijpers-Jagtman AM. Regulatory effects of FGF-2 on the growth of mandibular condyles and femoral heads from newborn rats. *Arch Oral Biol* 2005;50:959–969.