

Evaluation of the Relationship between the Impacted Mandibular Third Molar and the Inferior Alveolar Canal on Panoramic Radiograph

Quan CHEN¹, Deng Gao LIU², Gang ZHANG², Xu Chen MA²

Objective: To evaluate the diagnostic accuracy of the panoramic radiograph in judging the relationship between the impacted mandibular third molar (IMTM) and the inferior alveolar canal (IAC) by cone-beam computed tomography (CBCT) and give guidelines for using radiological examinations before IMTM extraction.

Methods: A total of 1735 IMTMs on panoramic radiographs were analysed and classified into three classes according to the relationship between the IMTMs and the IAC. A total of 126 IMTMs superimposing on the canal partially or touching the canal in line on panoramic radiographs were examined by CBCT. Nine radiographic signs were observed by two radiologists respectively and multivariate logistic regression analysis was performed.

Results: 8.7% of IMTMs have superimposition or a linear touching relationship with the IAC on panoramic radiographs. Of these IMTMs, 52.4% impinged and broke the IAC in CBCT images. Two radiologic signs on panoramic radiographs, including interruption of the radiopaque border of the canal ($P = 0.009$), and interruption of the alveolar lamina dura and periodontal space ($P = 0.007$), were statistically significant in predicting the impingement of the IAC.

Conclusion: Panoramic radiography can be used to screen out high-risk cases of inferior alveolar nerve injury before the IMTM extraction. Those IMTMs superimposing the canal partially or touching the canal in line on panoramic radiographs should be examined by CBCT further. Two features on panoramic radiographs, including interruption of the alveolar lamina dura and periodontal space, and interruption of the radiopaque border of the canal, were more valuable than other signs to predict impingement and interruption of the IAC wall.

Key words: cone-beam computed tomography, impacted mandibular third molar, inferior alveolar canal, panoramic radiography

One of the most serious complications of impacted mandibular third molar (IMTM) extraction is injury to the inferior alveolar nerve. The overall risk of the in-

ferior alveolar nerve injury ranges from 0.4% to 9.8%¹⁻¹⁰. The anatomical feature of this complication is the intimate contact between the IMTM and the inferior alveolar canal (IAC). Much valuable information about the peculiarities between these two structures can be obtained with the use of radiographs in dental practice. These help clinicians avoid the complication as much as possible before the extraction operation is begun. Several authors have identified some high-risk radiological signs associated with an intimate anatomical relationship between the IMTM and the IAC on periapical and panoramic radiographs. The question remains, which high-risk radiological signs are more effective and easier to use in dental practice?

With the development of computer technology, three-dimensional imaging diagnosis has been practiced for

1 Department of Oral and Maxillofacial Radiology and Outpatient Dental Center, Peking University School and Hospital of Stomatology, Beijing, P.R. China.

2 Department of Oral and Maxillofacial Radiology, Peking University School and Hospital of Stomatology, Beijing, P.R. China.

Corresponding author: Dr Xu Chen MA, Department of Oral and Maxillofacial Radiology, Peking University School and Hospital of Stomatology, #22 Zhongguancun Nandajie, Haidian District, Beijing 100081, P.R. China. Tel: 86-10-62179977 ext 2345; Fax: 86-10-62136628; Email: kqxcma@bjmu.edu.cn

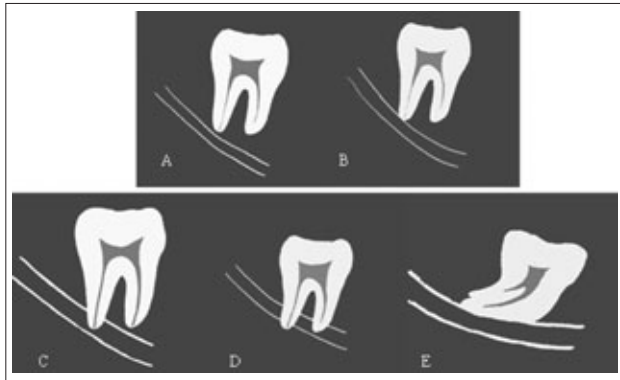


Fig 1 All of the IMTMs were classified into three classes according to the relationship between the IMTM and the IAC detected on panoramic radiographs: class A: the IMTMs did not touch the canal (Fig 1A); class B: the apex of the IMTM touched the canal (Fig 1B); class C: the IMTM superimposed the canal partly, or touched the canal in line (Fig 1C, D and E).

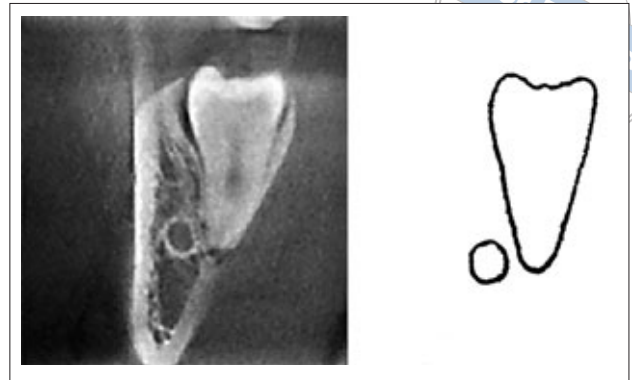


Fig 2 Type 1: the mandibular canal wall was intact and complete.

more than 10 years in dentistry. A series of cone-beam computed tomography (CBCT) instruments have been developed for dental use¹¹⁻¹³. The relationship between the IMTM and IAC can be diagnosed accurately by CBCT¹⁴⁻¹⁸. However, the cost and complexity of these machines, along with the problems associated with the relatively high dose of x-rays absorbed by the patient, limits the wide application of this technique^{13,19-21}.

The aim of this study was to evaluate the diagnostic accuracy of panoramic radiographs in judging the relationship between the IMTM and IAC and develop protocols for using CBCT. A cross-sectional study design and a diagnostic test were performed. The CBCT findings were regarded as the gold standard. Panoramic radiographs were used as an initial evaluation of the potential for any high-risk IAC injury related to the IMTM. CBCT findings were compared with panoramic radiographic signs to evaluate their diagnostic value. In this way, surgeons can screen out cases at high-risk for inferior alveolar nerve injury or decide whether a CBCT scan is needed in clinical situations.

The ethics committee of the Peking University Health Science Center approved the project. Informed consent forms were obtained from all the patients undergoing CBCT examination.

Materials and Methods

Patients and methods

The image information was collected from all of the people who accepted the panoramic radiography examination at the Department of Oral and Maxillofacial

Radiology, Peking University School and Hospital of Stomatology in June and July 2007. Patients with benign or malignant lesions around the IMTM were excluded from the present study. Patients without IMTM were also excluded. A total of 1073 patients (1735 IMTMs) were selected in the study. The IMTM was classified into three classes according to the relationship between the IMTM and the IAC on panoramic radiographs: class A, the IMTM did not touch the canal (Fig 1A); class B, the apex of the IMTM touched the canal (Fig 1B); class C, the IMTM superimposed the canal partly, or touched the canal in line (Fig 1C, D and E). In total, 84 patients (126 IMTMs) of class C were recalled and agreed to undergo the CBCT examination.

The panoramic radiograph was made with use of the Orthopantograph OP100 (Instrumentarium, Helsinki, Finland). The CBCT was taken by using a 3DX multi-image micro CT (J. Morita, Kyoto, Japan.). Exposure factors were set at 80 kV, 5 mA, and 17.5 seconds. The three-dimensional views were reconstructed from the raw data and optimised after selecting the region of interest and adjusting the angle and grey level. The slice interval and slice thickness were set at 1 mm. The voxel dimension was 125 μm \times 125 μm \times 125 μm .

Evaluation of the images

According to the analysis of CBCT three-dimensional images, the relationship between the IMTM and IAC was classified into two types: type 1, the IAC wall was complete whether the IMTM touched the canal or not (Figs 2 and 3); type 2, the IAC wall was impinged and broken by the IMTM at least on one image (Fig 4).

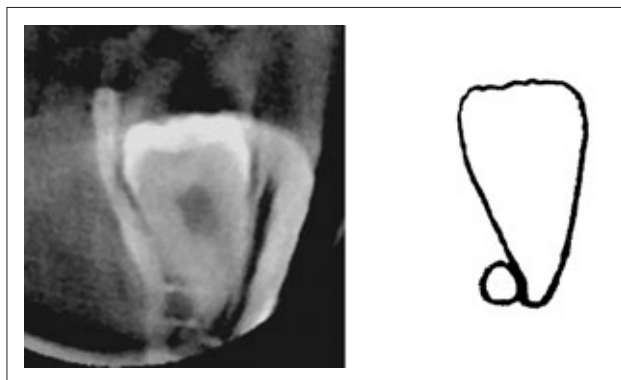


Fig 3 Type 1: the mandibular canal wall was complete in spite of the fact that the IMTM touched the canal wall.

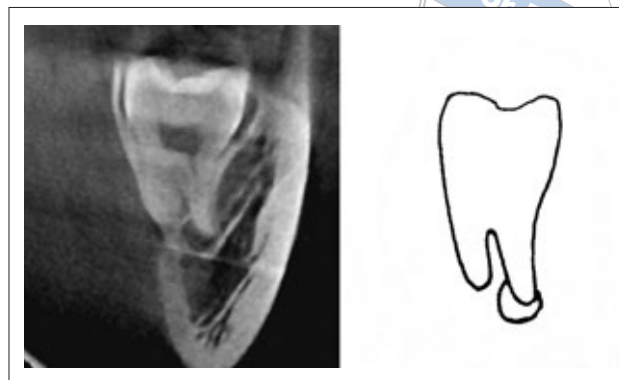


Fig 4 Type 2: the mandibular canal wall was impinged and broken by the IMTM.

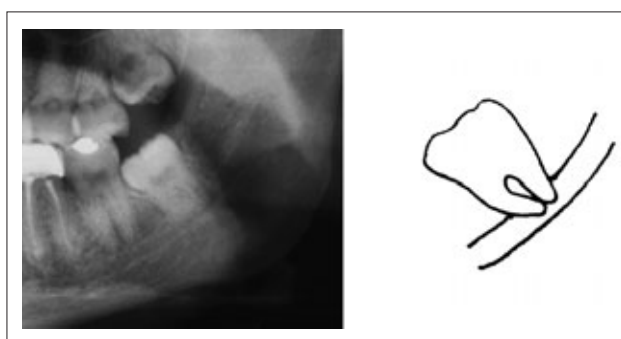


Fig 5 Interruption of the radiopaque border of the canal.

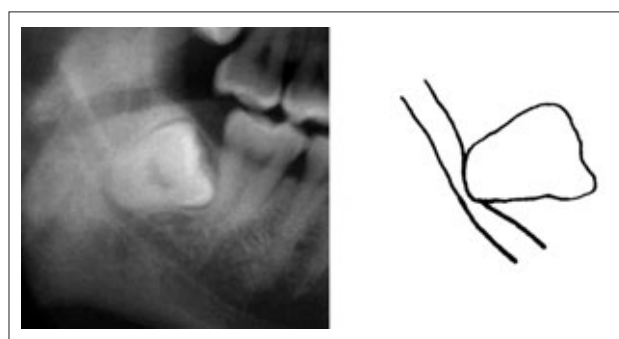

Fig 6 Narrowing of the diameter of the canal resulting from close proximity to the third molar.

Nine radiological signs, in terms of the IMTM and the IAC, were detected and evaluated for each of the panoramic radiographs^{1-3,6,9,10,22-32}.

- 1) Interruption of the radiopaque border of the canal: the radiopaque lines that constitute the IAC were discontinuous because the IMTM root was located within the canal (Fig 5).
- 2) Narrowing of diameter of the canal: the canal narrowed due to a disturbance by the root or the crown of the IMTM (Fig 6).
- 3) Diversion of the canal: a diversion of the canal was recognisable on the radiograph where the canal bent in proximity to the root or the crown of the IMTM (Fig 10).
- 4) Interruption of the alveolar lamina dura and periodontal space: the image of the alveolar lamina dura and periodontal space was discontinuous and blurry where the IMTM superimposed on the canal, while the image of the two structures was continuous and clear elsewhere (Fig 7).
- 5) Increased radiolucency: an increased radiolucency was detected where the mandibular canal crossed the IMTM (Fig 8).
- 6) Deflection of the roots by the canal: the root appeared to be deflected by or hooked around the canal (Fig 9).

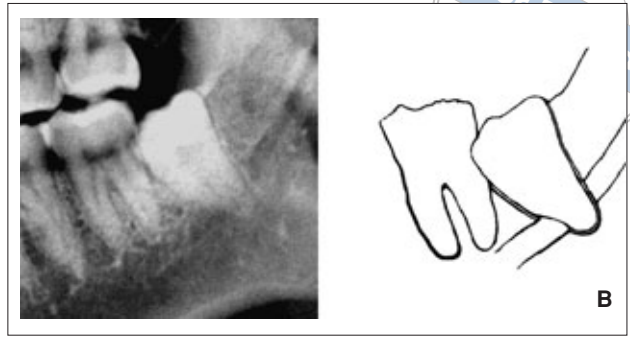
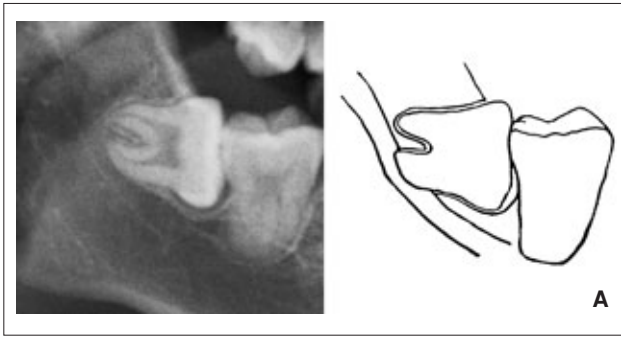

- 7) Narrowing of the root: there was a narrowing of the root like a waist where the canal crossed it.
- 8) The bifid apex: the apex of the tooth appeared bifid where the canal crossed it.
- 9) Developing roots: the root of the IMTM was still developing (Fig 11).

Two oral radiologists observed the CBCT images independently and reached a consensus. Three radiologists assessed the panoramic radiographs blindly and independently for the presence of the 9 radiological signs. When disagreement existed among the assessments of the three observers, consensus was reached by discussion.

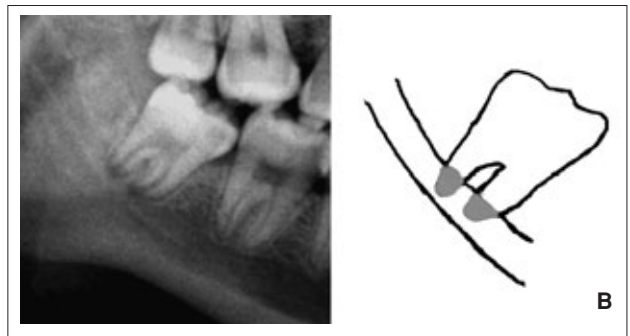
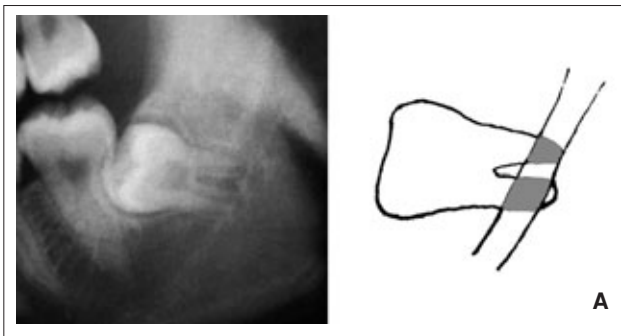
Statistical analysis

The component ratio of the three kinds of relationships between the IMTM and the canal on all panoramic radiographs was calculated.

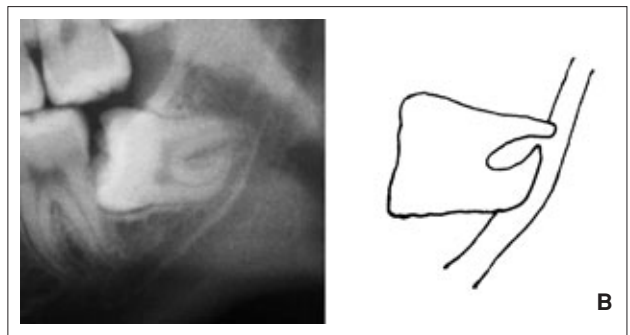
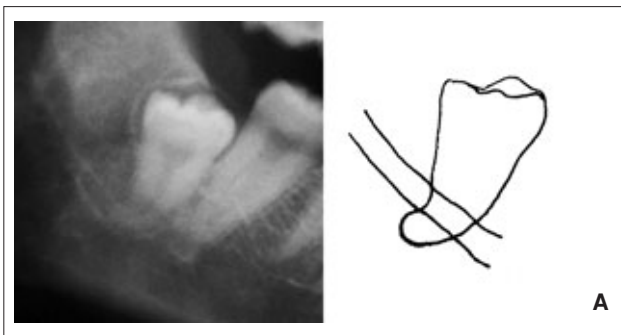
The diagnostic results of all of the cases examined by CBCT were regarded as the gold standard. The SPSS package (v13.0, SPSS, Chicago, IL) was used to perform the statistical analysis. A multivariate logistic regression analysis was performed to identify statistically signifi-



Figs 7A and B Interruption of the alveolar lamina dura and periodontal space.



Figs 8A and B Increased radiolucency.



Figs 9A and B Deflection of the roots by the canal. The root appeared deflected by the canal (Fig 9A). The root appeared to be hooked round the canal (Fig 9B).

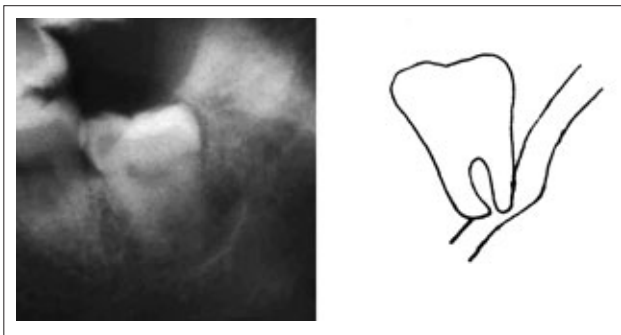


Fig 10 Diversion of the canal.

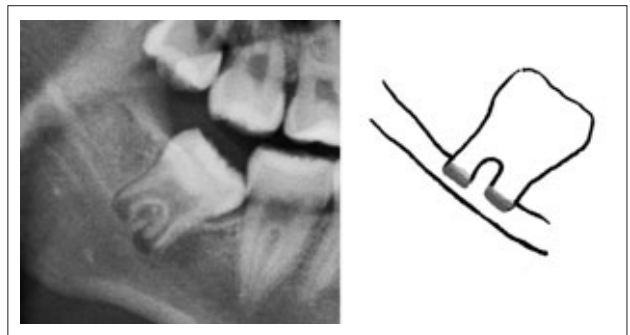


Fig 11 Developing roots: the root of the IMTM appeared to be still developing.

Table 1 The image findings of 126 IMTMs analyzed by CBCT and panoramic radiograph

CBCT	IMTM	Radiological sign on panoramic radiograph								
		Sign 1	Sign 2	Sign 3	Sign 4	Sign 5	Sign 6	Sign 7	Sign 8	Sign 9
Type 1	60	44	3	0	4	12	2	0	0	11
Type 2	66	60	4	1	16	19	0	0	0	14
Total	126	104	7	1	20	31	2	0	0	25

Type 1: mandibular canal wall was intact; Type 2: mandibular canal wall was broken

Sign 1: interruption of the radiopaque border of the canal; Sign 2: narrowing of the canal; Sign 3: diversion of the canal;

Sign 4: interruption of the alveolar lamina dura and periodontal space; Sign 5: increased radiolucency; Sign 6: deflection of the roots by the canal; Sign 7: narrowing of the root; Sign 8: the bifid apex; Sign 9: developing roots

Table 2 Sensitivity, specificity, accuracy, and positive and negative predictive values of two high-risk signs

Radiological sign on panoramic radiograph	Sensitivity	Specificity	Accuracy	PPV	NPV
Sign 1	90.9%	26.7%	60.3%	57.7%	72.7%
Sign 4	24.2%	93.3%	57.1%	80.0%	52.8%
Sign 1 + 4	21.2%	98.3%	57.9%	93.3%	53.2%

Sign 1: interruption of the radiopaque border of the canal; Sign 4: interruption of the alveolar lamina dura and periodontal space; PPV: positive predictive value; NPV: negative predictive value

cant panoramic radiological signs associated with whether the IMTM impinged and broke the IAC wall or not. The radiological signs were entered using backward stepwise regression. The signs were kept based on $P \leq 0.05$ and removed when $P \geq 0.1$. Sensitivity, specificity, accuracy, and positive and negative predictive values of panoramic radiological signs were calculated.

Results

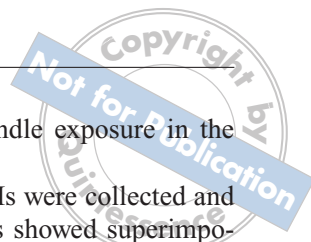
The component ratio of the relationship between the 1735 IMTMs and the canal on panoramic radiographs were as follows: class A 65.8%, 95% confidence interval (CI): 63.6%–68.0% (1141 IMTMs); class B 25.5%, 95% CI: 23.4%–27.6% (443 IMTMs); and class C, 8.7%, 95% CI: 7.4%–10.0% (151 IMTMs).

The 84 patients (126 IMTMs) undergoing the CBCT examination included 26 males and 58 females. Their ages ranged from 18 to 40 years with a mean of 25 years. Among them, 66 (52.4%) IMTMs impinged and broke the canal wall and the other 60 IMTMs did not break the canal wall on the images of CBCT. The image findings of all the cases by CBCT and panoramic radiography are shown in Table 1.

Of the nine signs used in the study, only two cases showed the ‘deflection of root’ feature, one case showed the ‘diversion of canal’ feature and no case showed the signs of ‘narrowing of root’ or ‘the bifid apex’ on panoramic radiographs. Hence, these four signs were excluded from the present study. The analysed result by multivariate logistic regression showed that only two panoramic radiological signs, namely interruption of the radiopaque border of the canal ($P = 0.009$) and interruption of the alveolar lamina dura and periodontal space ($P = 0.007$), were statistically significant in their association with the impingement of the IAC. Sensitivity, specificity, accuracy, and positive and negative predictive values of these two signs are presented in Table 2.

Discussion

Conventional assessment through the use of x-rays is essential to evaluating the topographic relationship between the IAC and the IMTM, and the panoramic radiograph is one of the most commonly used radiographic examinations for this purpose. In the present study, it was found that about 8.7% of the IMTMs did have superimposition or a linear touching relationship with the IAC



on panoramic radiographs. This was significantly lower than the result (61.7%) reported by Howe et al¹. This corresponds well to the nerve injury rate of 0.4% to 9.8% reported by some researchers. In this way, clinicians can identify the relatively high-risk patients before the IMTM extraction surgery.

When the panoramic image suggests a close relationship between the IMTM and the IAC, CBCT is recommended for further investigation to demonstrate the three-dimensional relationship between the two structures¹⁴⁻¹⁸. However, the evident drawbacks of CBCT are higher radiation dose and financial costs compared with panoramic radiography. If some credible information from panoramic radiographs could be obtained for the diagnosis of the real relationship between IMTM and IAC, it would be more helpful and convenient for the clinicians to make preparations for the extraction surgery.

Numerous clinical studies have been performed to determine what signs from panoramic radiographs suggest an intra-operative neurovascular bundle exposure or post-operative dysaesthesia. Blaeser reported that three features, including narrowing canal, increased radiolucency and interruption of the radiopaque border of the canal, were significantly correlated with the occurrence of post-operative dysaesthesia. The sensitivity and specificity were 100% and 33%, respectively²². In a report of 73 IMTMs, Monaco analysed five features of panoramic radiographs and compared them with an axial CT. He found that the predictive values of superimposition with the canal, increased radiolucency, interruption of the radiopaque border of the canal, narrowing of the canal and diversion of the canal were 38.5%, 73%, 71.4%, 78.6% and 100%, respectively.

If more than two features were found in one image, the predictive value was 100%²³. Tammissalo found neurovascular bundle exposure in 23 of 80 IMTMs during the extraction surgery, and 13 of 23 cases exhibited at least one of the following five radiological signs, namely, increased radiolucency, narrowing of the root, deflection of the roots by the canal, diversion of the canal, narrowing of the canal and interruption of the radiopaque border of the canal on the panoramic radiograph². Sedaghatfar reported that four features, including increased radiolucency, interruption of the radiopaque border of the canal, deflection of the roots by the canal and narrowing of the root had a significant statistical relationship with neurovascular exposure during IMTM extraction surgery.

The sensitivity, specificity and predictive value were 42% to 75%, 66% to 91% and 12% to 24%, respectively²⁷. Tantanapornkul suggested that the interruption of the radiopaque border of the canal feature could be

used to predict neurovascular bundle exposure in the IMTM extraction surgery¹⁷.

In the present study, 126 IMTMs were collected and examined by CBCT. All the cases showed superimposition or linear touching between the IMTM and IAC on the panoramic radiograph. In CBCT images, 66 IMTMs (52.4%) had impinged and broken the IAC. Hence, more attention should be paid to the patients whose IMTM had an intimate relationship with the IAC on a panoramic radiograph. The relationship between these two structures should be evaluated more accurately before the extraction surgery. CBCT examination should be performed for exact diagnosis if it is available¹⁴⁻¹⁸. Nine possible radiological signs of IMTM were evaluated that had been reported to correlate well with intra-operative neurovascular bundle exposure or post-operative dysaesthesia. In this study, it was found that only two signs, namely, interruption of the alveolar lamina dura and periodontal space, and interruption of the radiopaque border of the canal, were statistically significant to serve as predictive factors.

The panoramic radiological sign, interruption of the alveolar lamina dura and periodontal space, had not been reported to serve as a high-risk predictive factor for the IMTM. Normally, the alveolar lamina dura and the periodontal space were clear and continuous surrounding the root of a tooth on a radiograph. The sign of interruption of the alveolar lamina dura and periodontal space may be explained by the theory of silhouette sign³³. When the IMTM impinged and broke the mandibular canal wall, this sign was on the radiograph. In Maegawa's study of 47 IMTMs, six of the seven patients in whom an inferior alveolar nerve was visible after removal of the IMTM, exhibited interruption of the periodontal membrane space on the panoramic radiographs²⁶.

In conclusion, in the present study, it was found that approximately 8.5% of the IMTMs had a relatively intimate relationship with the IAC, as detected on panoramic radiographs. It corresponded well with the rate of inferior alveolar nerve injury during the IMTM extraction operation reported by many authors.

The fact that IMTMs partially superimposed on the canal or touching the canal asymptotically on panoramic radiographs could be used as a sign to identify the high-risk nerve injury cases. More than half of the IMTMs impinged and broke the IAC in CBCT images. Moreover, two features on panoramic radiographs, including interruption of the alveolar lamina dura and periodontal space, and interruption of the radiopaque border of the canal, were more accurate and valuable than other signs in predicting the actual impingement and interruption of the IAC wall.

References

1. Howe G, Poyton H. Prevention of damage to the inferior dental nerve during the extraction of mandibular third molars. *Br Dent J* 1960;109:355-363.
2. Tammissalo T, Happonen RP, Tammissalo EH. Stereographic assessment of mandibular canal in relation to the roots of impacted lower third molar using multiprojection narrow beam radiography. *Int J Oral Maxillofac Surg* 1992;21:85-89.
3. Kipp DP, Goldstein BH, Weiss WW, Jr. Dysesthesia after mandibular third molar surgery: a retrospective study and analysis of 1,377 surgical procedures. *J Am Dent Assoc* 1980;100:185-192.
4. Gulicher D, Gerlach KL. Sensory impairment of the lingual and inferior alveolar nerves following removal of impacted mandibular third molars. *Int J Oral Maxillofac Surg* 2001;30:306-312.
5. Wofford DT, Miller RI. Prospective study of dysesthesia following odontectomy of impacted mandibular third molars. *J Oral Maxillofac Surg* 1987;45:15-19.
6. Valmaseda-Castellon E, Berini-Aytes L, Gay-Escoda C. Inferior alveolar nerve damage after lower third molar surgical extraction: a prospective study of 1117 surgical extractions. *Oral Surg Oral Med Oral Pathol Oral Radiol Endod* 2001;92:377-383.
7. Bataineh AB. Sensory nerve impairment following mandibular third molar surgery. *J Oral Maxillofac Surg* 2001;59:1012-1017.
8. Carmichael FA, McGowan DA. Incidence of nerve damage following third molar removal: a West of Scotland Oral Surgery Research Group study. *Br J Oral Maxillofac Surg* 1992;30:78-82.
9. Smith AC, Barry SE, Chiong AY, Hadzakis D, Kha SL, Mok SC, et al. Inferior alveolar nerve damage following removal of mandibular third molar teeth. A prospective study using panoramic radiography. *Aust Dent J* 1997;42:149-152.
10. Rood JP, Shehab B. The radiological prediction of inferior alveolar nerve injury during 3rd-molar surgery. *Br J Oral Maxillofac Surg* 1990;28:20-25.
11. Mozzo P, Procacci C, Tacconi A, Martini PT, Andreis IAB. A new volumetric CT machine for dental imaging based on the cone-beam technique: preliminary results. *Eur Radiol* 1998;8:1558-1564.
12. Arai Y, Tammissalo E, Iwai K, Hashimoto K, Shinoda K. Development of a compact computed tomographic apparatus for dental use. *Dentomaxillofac Radiol* 1999;28:245-248.
13. Farman AG. Oral and maxillofacial radiology: the allegory of the cave revisited. *Oral Surg Oral Med Oral Pathol Oral Radiol Endod* 2008;105:133-135.
14. Kamburo lu K, Kiliç C, Ozen T, Yüksel SP. Measurements of mandibular canal region obtained by cone-beam computed tomography: a cadaveric study. *Oral Surg Oral Med Oral Pathol Oral Radiol Endod* 2009;107:e34-e42.
15. Snyder RL, Chandiramani SS, Scarfe WC, Scheetz JP, Farman AG. CBCT-simulated panoramic images for the assessment of mandibular third molar apices to the inferior alveolar canal. *Oral Surg Oral Med Oral Pathol Oral Radiol Endod* 2008;105:e59.
16. Neugebauer J, Shirani R, Mischkowski RA, Ritter L, Scheer M, Keeve E, et al. Comparison of cone-beam volumetric imaging and combined plain radiographs for localization of the mandibular canal before removal of impacted lower third molars. *Oral Surg Oral Med Oral Pathol Oral Radiol Endod* 2008;105:633-642.
17. Tantanapornkul W, Okouchi K, Fujiwara Y, Yamashiro M, Maruoka Y, Ohbayashi N, et al. A comparative study of cone-beam computed tomography and conventional panoramic radiography in assessing the topographic relationship between the mandibular canal and impacted third molars. *Oral Surg Oral Med Oral Pathol Oral Radiol Endod* 2007;103:253-259.
18. Ludlow JB, Laster WS, See M, Bailey LTJ, Hershey HG. Accuracy of measurements of mandibular anatomy in cone beam computed tomography images. *Oral Surg Oral Med Oral Pathol Oral Radiol Endod* 2007;103:534-542.
19. Garcia Silva MA, Wolf U, Heinicke F, Gründler K, Visser H, Hirsch E. Effective dosages for recording Veraviewepocs dental panoramic images: analog film, digital, and panoramic scout for CBCT. *Oral Surg Oral Med Oral Pathol Oral Radiol Endod* 2008;106:571-577.
20. Friedland B, Donoff B, Dodson TB. The use of 3-dimensional reconstructions to evaluate the anatomic relationship of the mandibular canal and impacted mandibular third molars. *J Oral Maxillofac Surg* 2008;66:1678-1685.
21. White SC, Pharoah MJ. The evolution and application of dental maxillofacial imaging modalities. *Dent Clin North Am* 2008;52:689-705.
22. Blaeser BF, August MA, Donoff RB, Kaban LB, Dodson TB. Panoramic radiographic risk factors for inferior alveolar nerve injury after third molar extraction. *J Oral Maxillofac Surg* 2003;61:417-421.
23. Monaco G, Montevecchi M, Bonetti GA, Gatto MRA, Checchi L. Reliability of panoramic radiography in evaluating the topographic relationship between the mandibular canal and impacted third molars. *J Am Dent Assoc* 2004;135:312-318.
24. Main L. Further roentgenographic study of mandibular third molars. *J Am Dent Assoc* 1938;25:1993-7.
25. Seward GR. Radiology in general dental practice. VIII. Assessment of lower third molars. *Br Dent J* 1963;115:45-51.
26. Maegawa H, Sano K, Kitagawa Y, Ogasawara T, Miyauchi K, Sekine J et al. Preoperative assessment of the relationship between the mandibular third molar and the mandibular canal by axial computed tomography with coronal and sagittal reconstruction. *Oral Surg Oral Med Oral Pathol Oral Radiol Endod* 2003;96:639-646.
27. Sedaghatfar M, August MA, Dodson TB. Panoramic radiographic findings as predictors of inferior alveolar nerve exposure following third molar extraction. *J Oral Maxillofac Surg* 2005;63:3-7.
28. Bell GW. Use of dental panoramic tomographs to predict the relation between mandibular third molar teeth and the inferior alveolar nerve – Radiological and surgical findings, and clinical outcome. *Br J Oral Maxillofac Surg* 2004;42:21-27.
29. Ohman A, Kivijarvi K, Blomback U, Flygare L. Pre-operative radiographic evaluation of lower third molars with computed tomography. *Dentomaxillofac Radiol* 2006;35:30-35.
30. Mahasantipiya PM, Savage NW, Monsour PAJ, Wilson RJ. Narrowing of the inferior dental canal in relation to the lower third molars. *Dentomaxillofac Radiol* 2005;34:154-163.
31. de Melo Albert DG, Gomes ACA, do Egito Vasconcelos BC, de Oliveira e Silva ED, Holanda GZ. Comparison of orthopantomographs and conventional tomography images for assessing the relationship between impacted lower third molars and the mandibular canal. *J Oral Maxillofac Surg* 2006;64:1030-1037.
32. Drage NA, Renton T. Inferior alveolar nerve injury related to mandibular third molar surgery: an unusual case presentation. *Oral Surg Oral Med Oral Pathol Oral Radiol Endod* 2002;93(3):358-361.
33. Longuet R, Phelan J, Tanous H, Bushong S. Criteria of the silhouette sign. *Radiol* 1977;122:581-585.