

# Effects of Radiation on the Expression of Nerve Growth Factor in Rat Submandibular Gland

Yan YU<sup>1</sup>, Yu Wei WU<sup>2</sup>, Ting HAO<sup>2</sup>, Shou Ping XU<sup>3</sup>, Zhi Min LI<sup>4</sup>, Zu Yan ZHANG<sup>1</sup>

**Objective:** To investigate the correlation between the expression of nerve growth factor (NGF) and tissue injury in irradiated rat submandibular gland.

**Methods:** The salivary gland regions of the rats were irradiated with a single dose of 15 Gy X-ray. The histopathological changes in the submandibular gland were observed, while the expression of NGF was determined by immunohistochemistry and real-time PCR.

**Results:** The weight of the body and submandibular gland decreased in the irradiated rats 30 days after irradiation, compared with the control group. There were also significant histopathological changes in the submandibular gland of the irradiated rats compared with the non-irradiated rats. The acinar cells and ducts were degenerated obviously. Fibrosis appeared around the ducts. The mRNA and protein expression of NGF in the submandibular gland decreased in the irradiated rats compared with the control group. Protein expression of NGF was even observed in the striated duct in the irradiated rats.

**Conclusion:** NGF may play an important role in protection of the submandibular glands of rats from radiation.

**Key words:** ionising radiation, nerve growth factor, submandibular gland

Radiotherapy is frequently used in the treatment of malignant tumours in the head and neck. However, xerostomia is probably the most common persistent oral sequela for patients who receive therapeutic doses of radiation for head and neck cancer<sup>1</sup>.

Irradiated serous salivary glands undergo interphase cell death by apoptosis, resulting in degenerative changes in serous acinar cells. However, more recent findings suggest that cell-membrane damage by radiation impairs receptor-cell signalling, which in turn leads to compromised and incomplete function<sup>2,3</sup>. Damage also occurs in the parenchyma of the salivary gland, and radiation-associated inflammation, vascular changes and oedema contribute to the overall extent of damage.

It is reported that some growth factors are important radioprotectors in the therapy of radiation injuries<sup>4,5</sup>, such as nerve growth factor (NGF). Although the best documented activity of NGF is on nerve cells, roles of NGF in tissue repair processes have been proposed. NGF affects haematopoietic and immune cells, which are important for radiation injuries<sup>6</sup>. Whether the expression of NGF in the submandibular gland is or is not changed after the radiation remains unexplored. The present study was designed to explore the expression of NGF in the submandibular gland after irradiation.

1 Department of Oral and Maxillofacial Radiology, Peking University School and Hospital of Stomatology, Beijing, P.R. China.

2 Department of Oral and Maxillofacial Surgery, Peking University School and Hospital of Stomatology, Beijing, P.R. China.

3 Department of Radiation Oncology, PLA General Hospital, Beijing, P.R. China.

4 Department of Oral and Maxillofacial Surgery, Jilin University School and Hospital of Stomatology, Changchun, P.R. China.

**Corresponding author:** Dr Zu Yan ZHANG, Department of Oral and Maxillofacial Radiology, Peking University School and Hospital of Stomatology, #22 Zhongguancun Nandajie, Haidian District, Beijing 100081, P.R. China. Tel: 86-10-62179977 ext 5325; Fax: 86-10-62173402. E-mail: zhangzy-bj@vip.sina.com

## Materials and methods

### *Animals and irradiation protocol*

Male Sprague-Dawley rats (body weight between 200 and 300 g) were divided into control groups and irradiated groups (10 rats in each group), and housed in cages under a 10:14 hour light:dark cycle for 1 week before the experiments. Food and water were given *ad libitum* with a soft diet provided for both control and irradiated rats. Prior to irradiation, the rats were anaesthetised by an intraperitoneal injection of sodium pentobarbital (40–50 mg/kg body weight). After being anaesthetised, the rats were tied on their backs to a wooden tablet that was separated into five lattices. The body, including the oral cavity, was shielded from irradiation with 8-mm-thick lead, with an opening for the salivary gland regions about 2 cm in width. The rats were put under the radioactive source. The machine (electron linear accelerator; SL-18, Philips, Holland) was operated at 6 MeV, with a dose rate of 4.0 Gy/min at 100 cm. The rats were irradiated with a single dose of 15 Gy X-rays, which is consistent with previous studies<sup>7,8</sup>. Animals in the control group were anaesthetised but were not irradiated. All experiments were approved by the Animal Care and Use Committee of Peking University.

### *Tissue samples and light microscopy*

The rats were sacrificed with an overdose of sodium pentobarbital (100 mg/kg body weight) as described above on the third and thirtieth day post-irradiation. The submandibular glands were isolated and weighed. Tissue samples for real-time PCR analysis were immediately frozen in liquid nitrogen and stored at -80°C. Samples for immunohistochemistry were freshly fixed in 4% paraformaldehyde in phosphate buffered saline (PBS). The specimens were dehydrated in graded alcohols and xylene, and embedded in paraffin. Sections (5 mm thick) were stained with conventional haematoxylin and eosin (H&E).

### *Real-time PCR*

Total RNA was extracted with TRIzol (Invitrogen, Carlsbad, CA, USA) in accordance with the manufacturer's instructions, and the integrity was evaluated by electrophoresis in 1% agarose gel. Real-time-PCR (RT-PCR) was conducted with an iScript cDNA Synthesis Kit (Bio-Rad, Hercules, CA, USA) in 20 µl reaction volume containing 1 µg of total RNA, incubated at 25°C for 5 min, transcribed at 42°C for 30 min, and terminated

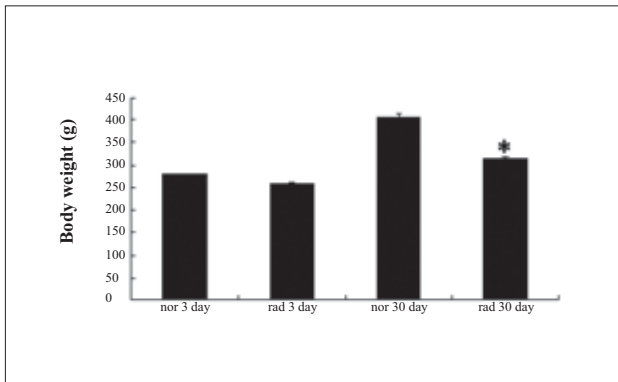
by heating at 85°C for 5 min. The synthesised cDNA was stored at -20°C until used. RT-PCR was performed with a Power SYBRGreen PCR Master Mix (Applied Biosystems, Foster City, CA, USA) using a 7500 RT-PCR System (Applied Biosystems). The reactions were run in duplicate with 1 µl of cDNA template in a 20 µl reaction volume with the program running for 50°C for 2 min, 95°C for 10 min, followed by 40 cycles of 94°C for 15 s and 60°C for 1 min. The amplification specificity was confirmed by melting curve. The mRNA level of the target gene was acquired from the value of threshold cycle (Ct) as a relative level to that of β-actin through the formula  $2^{-\Delta Ct}$  ( $\Delta Ct = \beta\text{-actin Ct} - \text{gene of interest Ct}$ ). The efficiency of the primers was confirmed by sequencing the conventional PCR products before applying for RT-PCR. The primers synthesised according to the sequences in previous reports were as follows: rat NGF sense/antisense, 5'-TAA GAG TAC CCA CAA AGT TT-3'/5'-CCT GCT TTC TGA CCA GTC TT-3'<sup>9</sup>; rat β-actin sense/antisense, 5'-TGA CAG-GAT GCA GAA GGA GA-3'/5'-TAG AGC CAC CAA TCC ACA CA-3'<sup>10</sup>.

### *Immunohistochemistry*

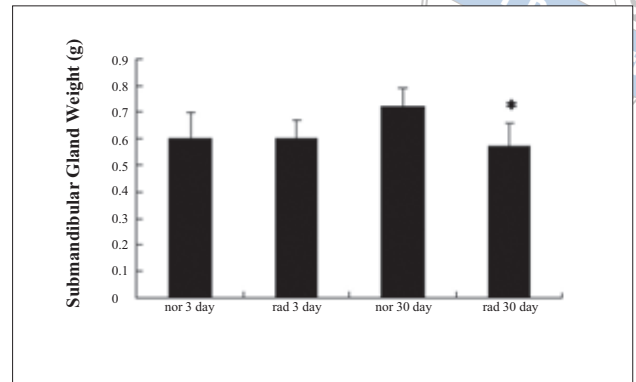
The immunostaining was performed by the three-step streptavidin-biotin-peroxidase method using commercially available kits (Zhongshan Golden Bridge Biological Technology, Beijing, P.R. China). After incubation with antibody against NGF (diluted at 1:100) for 12 h at 4°C, the sections were thoroughly washed with 0.1 M PBS, followed with incubation with horseradish peroxidase-conjugated secondary antibodies for 30 min at room temperature. After thorough washes with 0.1 mol/l PBS, the sections were visualised using 3, 3'-diaminobenzidine (Zhongshan Golden Bridge Biological Technology). The sections were finally counterstained with Mayer's haematoxylin.

### *Statistical analysis*

All values were reported as mean ± standard errors (SE) and were tested for statistical significance compared with the control group by an unpaired Student *t* test. Values of  $P < 0.05$  were considered to be statistically significant.



**Fig 1** Body weight of control and irradiated rats on day 3 and day 30 post-irradiation. Data are means  $\pm$  SE; \* $P < 0.05$ ; nor = normal; rad = radiation.



**Fig 2** Submandibular gland weights of control and irradiated rats on days 3 and day 30 post-irradiation. Data are means  $\pm$  SE; \* $P < 0.05$  vs. control group; nor = normal; rad = radiation.

## Results

### *Body weight, submandibular gland weight*

On day 3 and day 30 post-irradiation, body weights of the irradiated group significantly decreased by 7.86% and 22.84%, compared with the control group, respectively (Fig 1). Figure 2 shows the effect of radiation on the wet weight of the submandibular glands. On day 30 post-irradiation, the weights of the dissected submandibular glands from irradiated rats significantly decreased by 20.37% compared with the control rats.

### *Morphology change in irradiated rats*

Compared with the control group, degenerative changes in the submandibular glands of irradiated rats were observed after irradiation (Fig 3). The cells were replaced by fibrosis. Vascular congestion and ductal ectasia were observed on day 30 after irradiation (Fig 3C). A large scale of atrophy and disappearance of acinar cells were observed on day 30 post-irradiation (Fig 3D). No obvious inflammation was found after irradiation.

### *NGF expression in irradiated rats*

RT-PCR was used to assess NGF mRNA levels in rat submandibular glands on day 3 and day 30 post-irradiation. Densitometry analysis (Fig 4) revealed that the NGF mRNA level in the submandibular glands of irradiated rats decreased to 20% of that in the non-irradiated

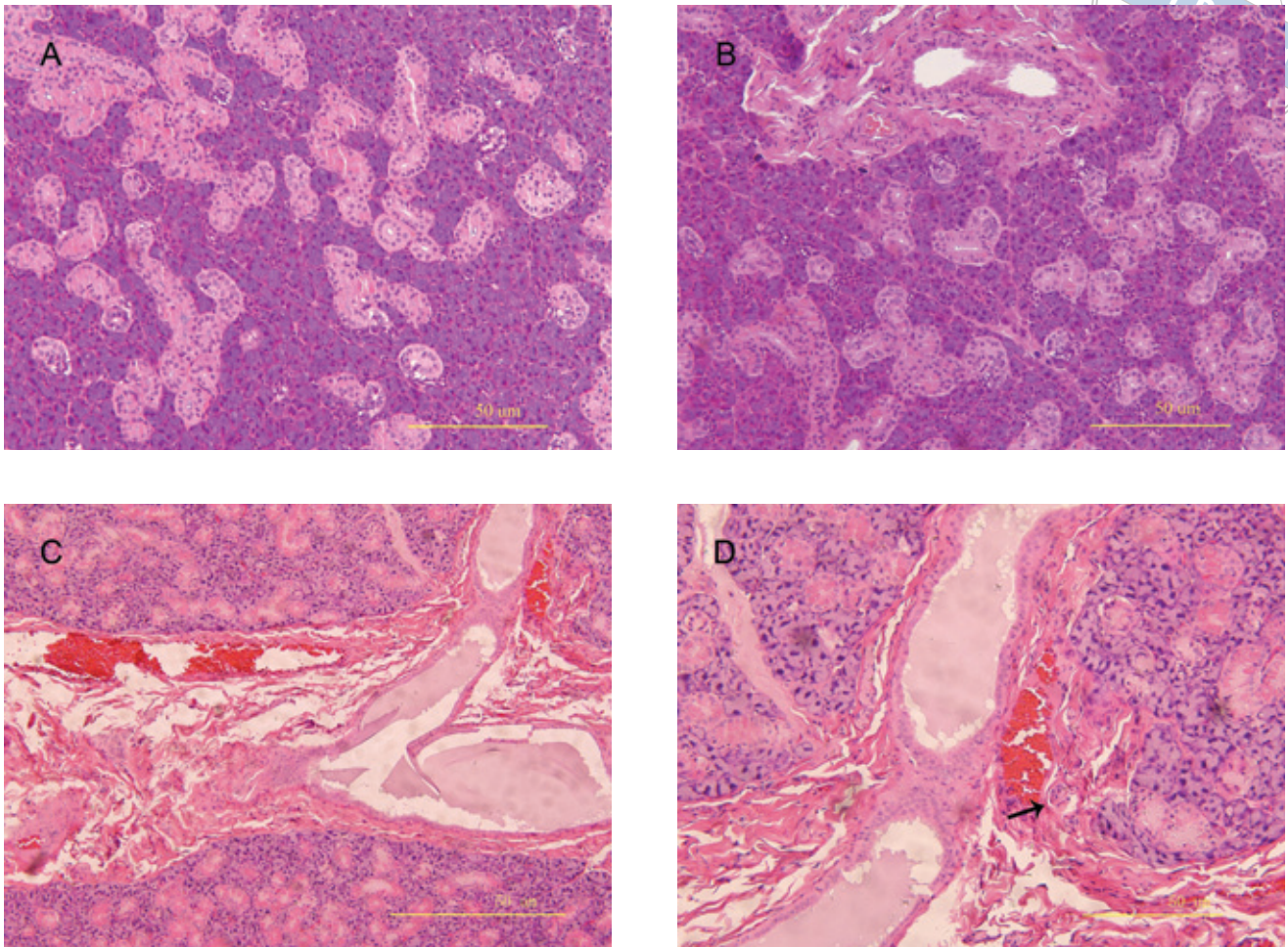
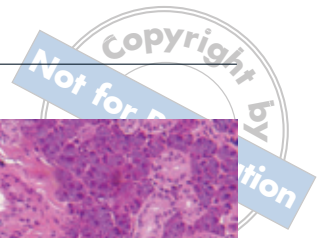rats on day 3 post-irradiation and decreased further to 12.5% of that in the non-irradiated rats on day 30 post-irradiation.

Immunostaining of NGF was mainly detected in the granular convoluted tubule cells, in the submandibular glands of non-irradiated rats (Fig 5). Decreased immunostaining of NGF was seen in the submandibular glands of irradiated rats on day 3 (Fig 5B) and day 30 (Fig 5D) after irradiation. Moreover, NGF was also observed in the cells of the striated ducts in the submandibular glands of irradiated rats on day 3 and day 30 post-irradiation, while negative staining in the cells of the striated duct was seen in the control group.

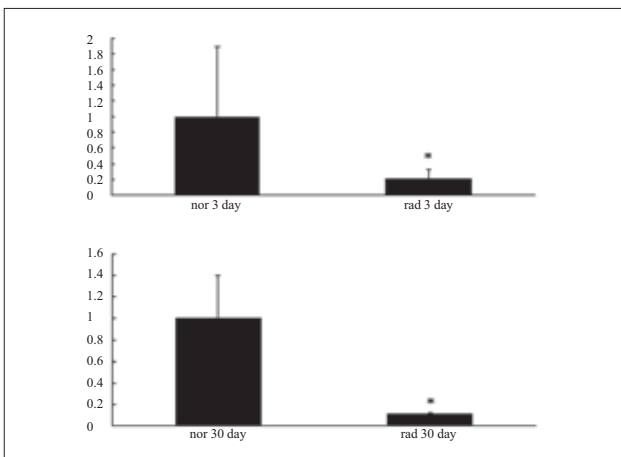
## Discussion

In the present study, decreases in body weight and gland weight were observed in the irradiated rats on day 30 post-irradiation, which are consistent with previous reports<sup>11</sup>. The decrease in body weight may be due to the decreased food and water intake after irradiation. The decrease in gland weight may be due to radiation-induced gland atrophy, as irradiation damages the acinar and ductal cells of the submandibular gland.

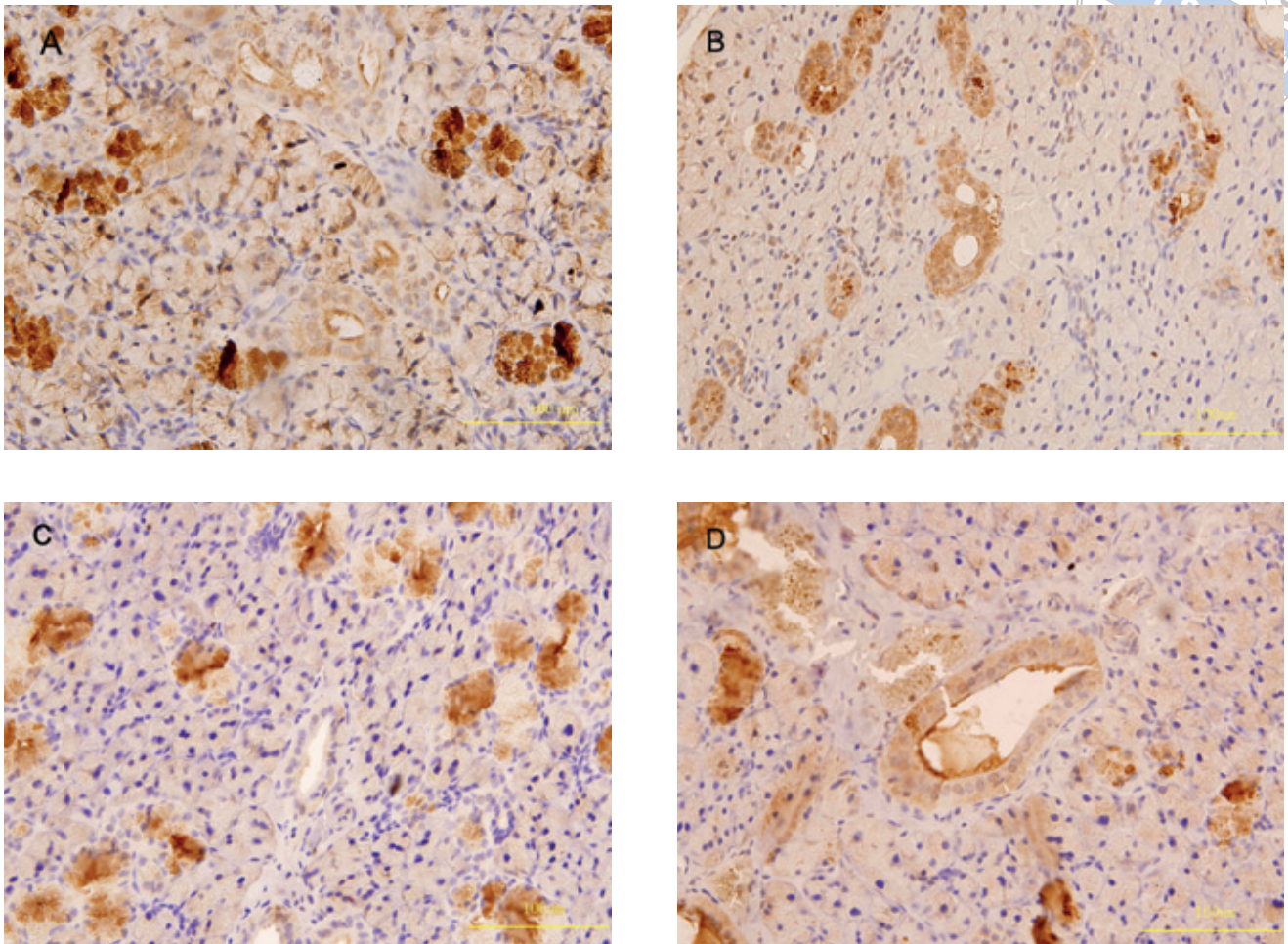
Therapeutic administration of irradiation is usually performed over several days to minimise damage to healthy tissues and organs. The results of fractionation protocol studies suggest that although damage can be delayed in some instances, salivary gland dysfunction still occurs in a dose-dependent fashion. Radiation-induced changes are dependent on the total dose delivered for both low- and high-rate administration. In



**Fig 3** Radiation-induced morphological changes in rat submandibular glands. The normal submandibular gland parenchyma is composed mainly of acinar cells, duct cells and granular convoluted tubules (A). There are limited acinar and ductal cell changes in the gland on day 3 after irradiation (B). The cells were replaced by fibrosis. Vascular congestion and ductal ectasia was observed on day 30 after irradiation (C). A large scale of atrophy and disappearance of acinar cells (indicated by arrow) were observed (D).



**Fig 4** RT-PCR analysis for NGF expression in the submandibular gland. The mRNA expression of NGF was down-regulated significantly on both day 3 and day 30 after irradiation. The y axis represents relative expression compared to normal. \* $P < 0.05$  vs. control group; nor = normal; rad = radiation.



**Fig 5** Immunohistochemistry of NGF in rat submandibular glands. Immunostaining of NGF decreased in the submandibular glands of irradiated rats on day 3 (B) and day 30 (D) after irradiation. The staining of NGF was also observed in the cells of the striated ducts in the submandibular glands of irradiated rats on day 3 and day 30, while negative staining was present in the cells of the striated duct in the control group (A and C).

the rats, a single dose below 20 Gy radiation induced damage equivalent to clinical radiotherapy tissue damage<sup>8</sup>. Functional studies in the rat suggest a ceiling dose equivalent to acute administration of 15 Gy. When high acute doses are employed, much of this initial decrease in body weight appears to result from decreased food and water intake due to radiation-induced transient irritation of oropharyngeal tissues.

Studies in rats reported a 40% reduction in salivary flow rates with single doses of 5 or 10 Gy, and approximately 60% reduction following 15 or 20 Gy 3 days after treatment<sup>8</sup>. The maximum changes in the flow rate and phosphate and calcium concentrations and the largest changes in sodium and potassium concentrations

were also observed within this period<sup>8</sup>. Loss of serous acinar cells has been linked to reductions in salivary flow, since these cells account for about 80% of parotid gland volume and are responsible for water and protein secretion. At day 30, however, the rate of secretion of amylase decreased again, and this may represent incomplete tissue regeneration and late stromal effects such as delayed vascular damage<sup>8</sup>. In general, chronic dysfunction has been attributed to loss or impairment of serous acinar cells and replacement by connective tissue and fibrosis<sup>12</sup>. Many studies have reported significant acinar cell atrophy at chronic time-points<sup>13</sup>.

In the present study, the authors found that the endogenous expression and distribution of NGF in

the submandibular gland decreased after irradiation, compared with the non-irradiated gland. This is the first report about decreased expression of NGF in the submandibular gland after irradiation. The expression of NGF in the submandibular gland decreased after irradiation, which is consistent with a previous report on granulation tissues after total-body irradiation<sup>14</sup>. NGF might contribute to the repair process by influencing the inflammatory response and promoting angiogenesis, according to previous studies<sup>15,16</sup>. Further research is required to find out whether the tissue repair ability of NGF can be applied in the submandibular gland.

## References

1. Sciubba JJ, Goldenberg D. Oral complications of radiotherapy. *Lancet Oncol* 2006;7:175-183.
2. Paardekooper GM, Cammelli S, Zeilstra LJ, Coppes RP, Konings AW. Radiation-induced apoptosis in relation to acute impairment of rat salivary gland function. *Int J Radiat Biol* 1998;73:641-648.
3. Konings AW, Coppes RP, Vissink A. On the mechanism of salivary gland radiosensitivity. *Int J Radiat Oncol Biol Phys* 2005;62:1187-1194.
4. Nair CK, Parida DK, Nomura T. Radioprotectors in radiotherapy. *J Radiat Res (Tokyo)* 2001;42:21-37.
5. Schooltink H, Rose-John S. Cytokines as therapeutic drugs. *J Interferon Cytokine Res* 2002;22:505-516.
6. Simone MD, De Santis S, Vigneti E, Papa G, Amadori S, Aloe L. Nerve growth factor: a survey of activity on immune and hematopoietic cells. *Hematol Oncol* 1999;17:1-10.
7. Vissink A, Kalicharan D, S-Gravenmade EJ, Jongebloed WL, Ligeon EE, Nieuwenhuis P et al. Acute irradiation effects on morphology and function of rat submandibular glands. *J Oral Pathol Med* 1991;20:449-456.
8. Vissink A, S-Gravenmade EJ, Ligeon EE, Konings WT. A functional and chemical study of radiation effects on rat parotid and submandibular/sublingual glands. *Radiat Res* 1990;124:259-265.
9. Yan J, Welsh AM, Bora SH, Snyder EY, Koliatsos VE. Differentiation and tropic/trophic effects of exogenous neural precursors in the adult spinal cord. *J Comp Neurol* 2004;480:101-114.
10. Tian SP, Yao HJ, Deng X, Xu XB, Qin GZ, Chan ZL. Characterization and expression of beta-1,3-glucanase genes in jujube fruit induced by the microbial biocontrol agent *Cryptococcus laurentii*. *Phytopathology* 2007;97:260-268.
11. Nagler RM, Baum BJ, Fox PC. A 2 week pair-fed study of early X-irradiation effects on rat major salivary gland function. *Arch Oral Biol* 1996;41:713-717.
12. Li J, Shan Z, Ou G, Liu X, Zhang C, Baum BJ et al. Structural and functional characteristics of irradiation damage to parotid glands in the miniature pig. *Int J Radiat Oncol Biol Phys* 2005;62:1510-1516.
13. Muhvic-Urek M, Bralic M, Curic S, Pezelj-Ribaric S, Borcic J, Tomac J. Imbalance between apoptosis and proliferation causes late radiation damage of salivary gland in mouse. *Physiol Res* 2006;55:89-95.
14. Shi CM, Qu JF, Cheng TM. Effects of the nerve growth factor on the survival and wound healing in mice with combined radiation and wound injury. *J Radiat Res (Tokyo)* 2003;44:223-228.
15. Matsuda H, Koyama H, Sato H, Sawada J, Itakura A, Tanaka A et al. Role of nerve growth factor in cutaneous wound healing: accelerating effects in normal and healing-impaired diabetic mice. *J Exp Med* 1998;187:297-306.
16. Bernabei R, Landi F, Bonini S, Onder G, Lanbiase A, Pola R et al. Effect of topical application of nerve-growth factor on pressure ulcers. *Lancet* 1999;354:307.