



Open Reduction and Rigid Internal Fixation of Dislocated Condylar Fractures: A Long-term Follow-up of 25 Patients

Dong OUYANG¹, Xiao Ming GU², De Lin LEI³

Objective: To evaluate the long-term results of open reduction and rigid internal fixation for treatment of dislocated condylar process fractures.

Methods: Twenty-five patients with dislocated condylar fracture who underwent open reduction and rigid internal fixation were followed up for an average of 4.5 years and evaluated on the basis of occlusion, temporomandibular joint (TMJ) function and radiographs.

Results: Clinically, both occlusion and TMJ function were satisfactory. Generally, the dislocated condyles were well repositioned into the glenoid fossa after rigid internal fixation and remained in the position during the follow-up on the radiographs.

Conclusion: Open reduction and rigid internal fixation could achieve satisfactory results for the treatment of dislocated condylar fractures.

Key words: condylar process fracture, rigid internal fixation

Although several studies about the effects of rigid internal fixation on dislocated condylar fracture have been reported¹⁻³, the period of follow-up for those cases may not be sufficiently long, and they also lack detailed radiological analysis on changes of the condylar configuration. This study retrospectively reviewed, on the basis of physical examination and radiographs, the effects of the treatment for 25 patients with dislocated condylar fractures who underwent open reduction and rigid internal fixation and were followed up for an average of 4.5 years.

Patients and methods

General data

Twenty-five male patients aged 17 to 32 years with dislocated condylar fractures who underwent open reduction and rigid internal fixation from January 1989 to January 1996 (Affiliated Stomatological Hospital of The Fourth Military Medical University) were included. All the patients had complete clinical records including pre- and postoperative radiographs. There were 31 condylar fractures, one of which had not been given rigid internal fixation due to a high condylar fracture. The patients were followed up for an average of 4.5 years (2 to 6 years).

Operation procedure

The procedure used small-scale pure titanium plates and screws provided by Xi'an Zhongbang Titanium Biological Materials Co. Ltd. Temporal, submandibular and preauricular coronal stick-shaped incisions were made so as to fully expose the surgical areas. The capsular incision was changed from the usual vertical or

1 Department of Stomatology, Beijing Municipal Corps Hospital, Beijing, P.R. China.

2 General Hospital of Chinese People's Armed Police Forces, Beijing, P.R. China.

3 Affiliated Stomatological Hospital of the Fourth Military Medical University, Xi'an, P.R. China.

Corresponding author: Dr Dong OUYANG, Department of Stomatology, Beijing Municipal Corps Hospital, Beijing 100027, P.R. China; Tel: 86-10-64161188 ext 31599; E-mail: ouyd88@163.com

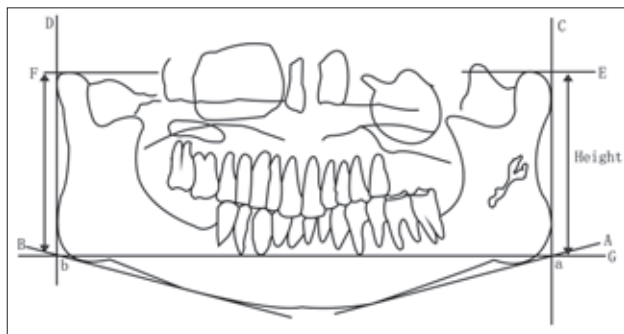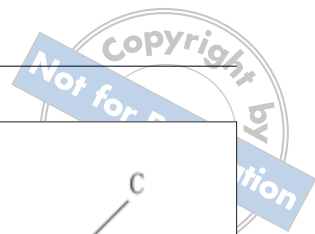


Fig 1 Measurement of ascending ramus height.

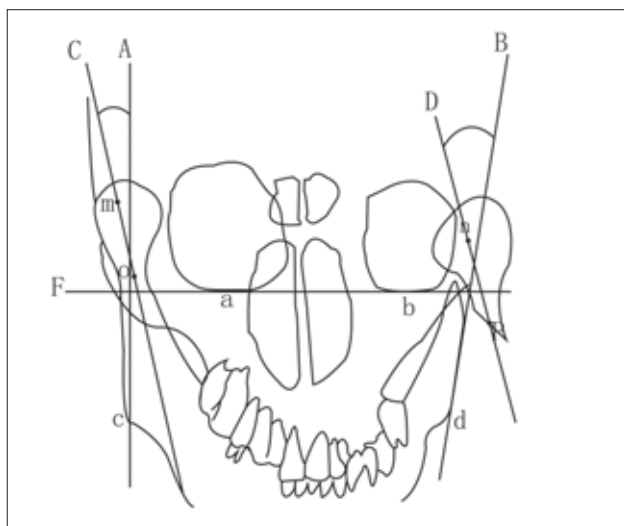


Fig 2 Measurement of intersection angle between condylar process and mandibular body.

preauricular, and coronal stick-shaped incisions were improved. When all the relevant anatomical structures were exposed and separated, the joint disk was first repositioned and then the condylar process was repositioned, with its distal end aligned with the ascending ramus, and fixed with titanium mini-plates.

Efficacy evaluation

Measurement of ascending ramus heights

A panoramic tomograph (PT) was placed on a film viewer and the outline of the mandible was delineated with a pencil. Lines A, B, C, D, E, F and G were drawn, as indicated in Figure 1. Lines A and B were the tangents of the lower edge of the mandible. Lines C and D were the tangents of the back edge of the mandible. Lines E and F were the tangents of the highest condylar process. Line G was drawn between points a and b, which were the

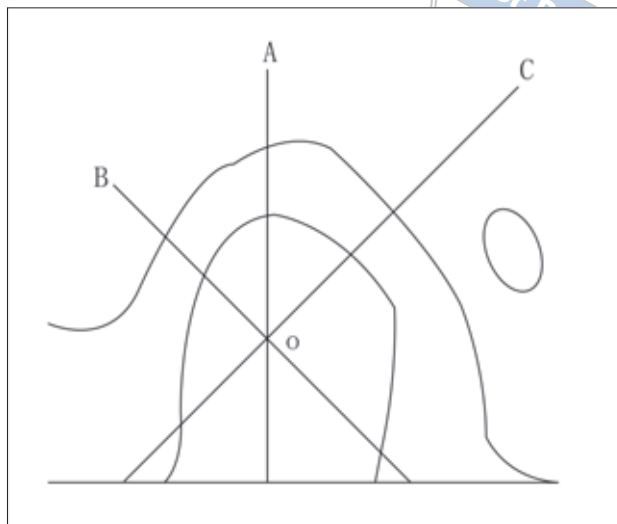


Fig 3 Measurement of joint space.

intersections of lines C and A and lines D and B, respectively. The height of the ascending ramus was measured as the distance between line E or line F and line G.

Measurement of intersection angles between condylar process and mandibular body

A mandibular posteroanterior film (MPA) was placed on a film viewer and the outlines of the orbits and mandible were delineated with a pencil. As shown in Figure 2, line F was drawn through the lowest points (a and b) of the orbits and then lines A and B were drawn through the mandibular angle points (c and d, respectively) perpendicularly to line F. Lines C and D were drawn through points m and n, respectively (midpoints of the condylar processes at the widest), and point o (midpoint of the condylar process at the narrowest) or point p (midpoint of the fractured end), respectively. The angles between the condylar process and mandibular body were measured as the angles between lines A and C and lines B and D, respectively.

Measurement of joint space (Schuller's projection)

The joint space was measured based on methods proposed by Zhang⁴. A Schuller position film was placed on a film viewer and the outlines of the condylar process, glenoid fossa and surrounding structures were delineated with a pencil. Lines A, B and C were drawn through the midpoint of the condylar process (Fig 3). The anterior joint space, superior joint space and posterior joint space were measured.

Table 1 Radiograph measurements of 25 patients with condylar fractures before and after rigid internal fixation and during follow-ups ($x \pm s$)

	Injured side			Normal side
	Before RIF	After RIF	At follow-ups	
I (mm)	69.50 ± 10.95	76.60 ± 5.72	73.20 ± 4.23	76.30 ± 4.20
II (°)	58.84 ± 24.24	9.29 ± 16.12	9.39 ± 5.89	5.39 ± 3.89
III (mm)	3.80 ± 0.62	2.27 ± 0.32	2.43 ± 0.50	3.65 ± 0.32
IV (mm)	1.32 ± 0.92	2.42 ± 1.96	2.36 ± 0.56	2.75 ± 0.45
V (mm)	3.83 ± 0.74	2.39 ± 0.41	2.40 ± 0.63	2.70 ± 0.41

Notes: I: mandibular ascending ramus height in PT; II: angle between condylar and mandibular body in MPA; III: superior joint space; IV: anterior joint space; V: posterior joint space; RIF: rigid internal fixation.

Clinical examinations

Clinical examinations included maximum mouth opening, temporomandibular joint (TMJ) noise, muscle and joint pain and occlusion.

Results

Before rigid internal fixation, the height of the ascending ramus of the injured side was significantly shorter than that of the normal side (Table 1 and Fig 4). After rigid internal fixation, the postoperative and follow-up heights of the ascending ramus showed almost no difference from the normal side (Table 1 and Fig 5). However, in eight cases a blurred cortical edge of the condyle or partly or completely absorbed condyle were found. The intersection angle between the condylar process and the mandibular body was significantly reduced from 58.84 ± 24.24 degrees to 9.29 ± 16.12 degrees after rigid internal fixation, and remained bigger than that of the normal side during the follow-up (Table 1). The anterior joint space was significantly increased from 1.32 ± 0.92 mm to 2.42 ± 1.96 mm after rigid internal fixation, and remained a little smaller than that of the normal side during the follow-up. The posterior joint space significantly decreased from 3.83 ± 0.74 mm to 2.39 ± 0.41 mm after rigid internal fixation, and remained a little bigger than that of the normal side during the follow-up. Generally, most cases showed no difference in condyle configuration between the injured side and the normal side on the radiographs.

Clinically, both occlusion and TMJ function were satisfactory. Postoperative efficacy evaluation showed nine cases were excellent (36%), eight cases good (32%), seven cases medium (28%) and one case poor (4%).

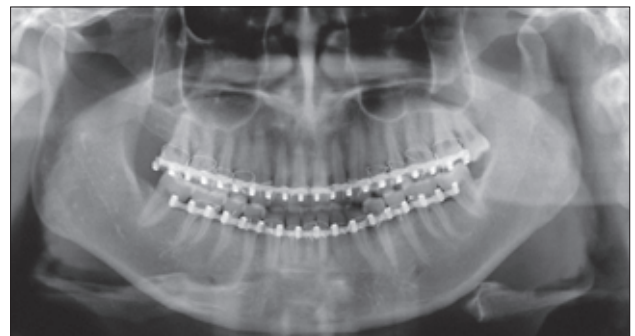


Fig 4 Panoramic tomograph before rigid internal fixation.

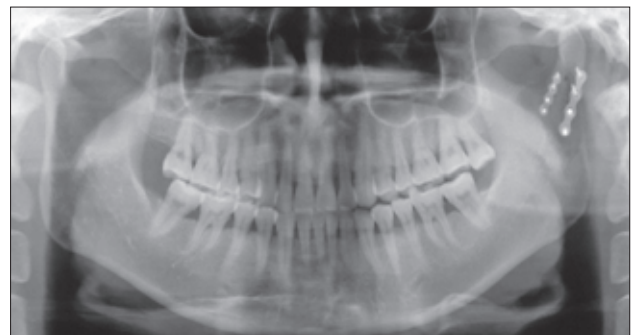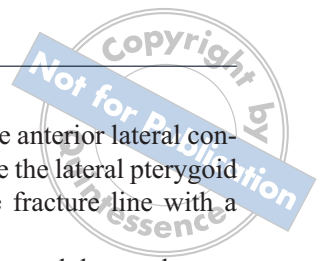


Fig 5 Panoramic tomograph after rigid internal fixation.

Discussion

Efficacy of rigid internal fixation of condylar fractures

After rigid internal fixation, there was almost no difference between the fractured and the normal sides on the radiographs, suggesting an excellent repositioning of the condylar process into the glenoid fossa. This was achieved mainly because rigid internal fixation could



provide three-dimensional stability for bone segments and ensure a quick recovery of local blood supply and rapid reproduction of osteoclasts and osteoblasts, which quickened the recovery of bone segments. In addition, intermaxillary fixation time was shortened with rigid internal fixation, so the patients could open their mouths and take in nutrients at an early stage¹. In this study, after mandibular traction for 3 to 7 days, patients could perform mouth opening and forward and sideward protraction. Since condylar fractures necessarily involve soft tissue injuries around joints, early mouth opening benefited the recovery of soft tissues around joints and also the articular discs and blood supply for condylar processes.

Strict operational requirements for rigid internal fixation

Before fixation, one should first carefully examine the courses of fracture lines and anatomical reduction of the fractured cross sections in order to identify the repositioning path and the plate location. The mini-plate should be modelled accurately before fixation so that it is tightly attached to the bone surface. When holes are prepared, the maxillary artery, carotid artery and jugular vein around the condyle should be carefully protected. When screws are tightened, the screws should be perpendicular to the bone surface to avoid the screw becoming loose. The fractured condylar segments are fixed first and then, after their anatomic reduction, the ascending ramus below them is fixed.

In this study, seven cases failed about 2 months postoperatively. Of these, three cases which were fixed with two single cortical screws showed a loosening of the screws, suggesting the screws were not sufficiently fastened. Therefore, three double cortical screws are recommended.

In the other four failed cases, titanium plates were fractured as they were placed near the anterior condyle and the sigmoid notch. As pterygoid muscle attaches to the medial condyle, the antero-medial condyle showed compressive stress while the postero-lateral side showed tensile stress. According to fixation principles in biomechanics, the mini-plates should be placed on the postero-lateral side with tensile stress.

If the condylar neck is fractured, a single plate may be applied as an external tension band at a stick-shaped incision, extending 20 mm from the front of the tragus to the hairline. If the base of condyle is fractured, a single plate may be applied as an external tension band at an incision along the lower edge of the mandibular angle or behind the mandible. In addition, supported

fixation should also be added at the anterior lateral condyle and the sigmoid notch because the lateral pterygoid muscle points are away from the fracture line with a large torque.

For fractures at or above the condylar neck, one L- or Y-shaped titanium mini-plate may be used with screws of 5 mm to fix the condylar process. The short arm of the L- or Y-shaped mini-plate should be placed at the ascending part or base part, with the L-shaped right angle forward. This could not only solve the difficulty in fixing the condylar neck, but also prevent the deviation of fractured segments due to the mini-plate's resistance against the bending force.

Effects on condylar bone change

Postoperative radiographic examination showed that in most cases the bone structure of the fractured side was almost the same as that of the normal side. However, some cases showed blurred condyle cortical edges and a partially or completely absorbed condylar process. The reason for these observations was unknown. They may be due to severe dislocation of the fractured condyle.

In conclusion, open reduction and rigid internal fixation could achieve satisfactory results for the treatment of dislocated condylar fractures.

References

1. Hibi H, Saeaki Y, Ueda M. Modified osteosynthesis for condylar neck fractures in atrophic mandibles. *Int J Oral Maxillofac Surg* 1997;26:348–350.
2. Widmark G, Bagenholm T, Kahnberg KE et al. Open reduction of subcondylar fractures. A study of functional rehabilitation. *Int J Oral Maxillofac Surg* 1996;25:107–111
3. Worsaae N, Thom J. Surgical versus nonsurgical treatment of unilateral dislocated low subcondylar fracture: A clinical study of 52 cases. *J Oral Maxillofac Surg* 1994;52:353–360.
4. Zhang ZK, Fu MK, Zou ZJ. *Temporomandibular Joint Disease* [in Chinese]. Beijing: People's Medical Publishing House, 1987.