

# Platelet-Rich Fibrin in Treatment of Periapical Lesions: a Novel Therapeutic Option

N SHUBHASHINI<sup>1</sup>, R Vinaya KUMAR<sup>2</sup>, A.S. SHIJA<sup>1</sup>, Shuaib RAZVI<sup>3</sup>

*In the present case of a 35-year old patient, platelet-rich fibrin, which is an autologous platelet concentrate, was used to fill the osseous defect following surgery. The case was assessed both clinically and radiographically for a period of 9 months.*

**Key words:** bone regeneration, periapical surgery, platelet-rich fibrin

In 1996, Sumi et al reported periapical surgery as one of the least understood and most inadequately performed of all oral surgical techniques<sup>1</sup>. Nonetheless, Cohn proposed periapical surgery as a predictable treatment option when root-end canal treatment is either not possible or fails<sup>1</sup>. The success rate varies between 37% and 91%<sup>2</sup>.

Although regenerative techniques have become a standard of care in periodontology and implant dentistry, these techniques have yet to be established in endodontic surgery<sup>3</sup>. Bone grafts and bone regeneration materials are being used in periapical surgery with varying degrees of success. However, the key to tissue regeneration is to stimulate a coordinated cascade of healing events that can result in integrated tissue formation. This is possible only with the use of growth factors, extracellular matrix and bone morphogenetic proteins instead of routinely used synthetic bone grafts, as the latter induce bone regeneration by osteoconduction, while the former stimulate regeneration by osteoinduction<sup>4</sup>.

The need for these biological modulators resulted in the development of Platelet-Rich Plasma (PRP) by Whitmen et al in 1997<sup>4</sup>. Subsequently, a second-generation platelet concentrate was developed in France by Choukroun et al, named Platelet-Rich Fibrin (PRF). Its advantages over PRP include ease of preparation/application, minimal expense, and lack of biochemical modification (no bovine thrombin or anticoagulant is required)<sup>5</sup>.

However, to our knowledge there is no report in endodontic literature regarding the use of this autologous healing biomaterial in periradicular surgery despite its widespread use in medicine and other specialties of dentistry. The present case evaluates the bone regeneration achieved using PRF in endodontically induced periapical lesions over a period of 9 months.

## Case report

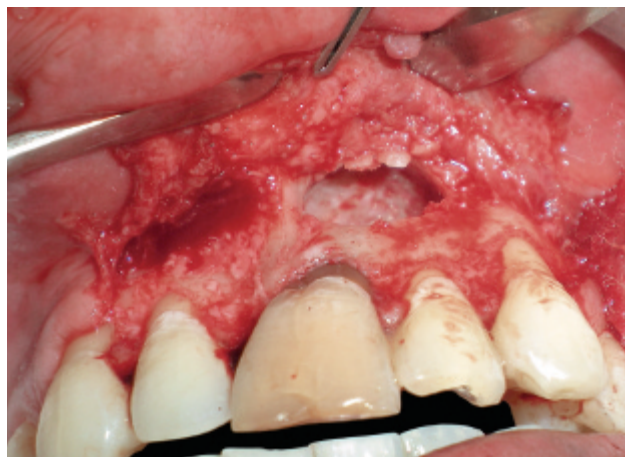A 35-year old male patient reported to the hospital with a complaint of discharge in relation to the left maxillary incisors. Past dental history revealed a history of trauma two months back with the central incisor being tender on percussion. On further questioning, the patient disclosed a root canal treatment done to the left lateral incisor 20 years back. An intraoral examination revealed a sinus opening with discharge located distally to the apical region of the central incisor. Thermal and electric pulp tests showed that the central incisor did not respond to vitality tests. Furthermore, the occlusal radiograph showed a well-defined radiolucency in relation to 21 and 22. It was decided to perform a periradicular surgery in the region as this case fit the indication for the same.

1 Department of Conservative Dentistry & Endodontics, RajaRajeswari Dental College & Hospital, Ramohalli Cross, Kumbalgodu, Karnataka, India.

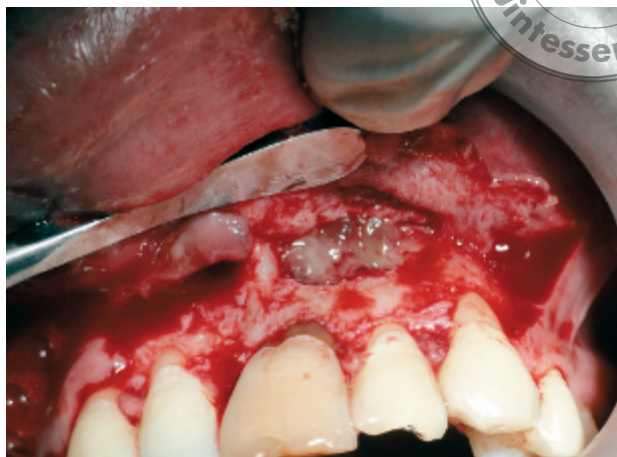2 Department of Periodontics, RajaRajeswari Dental College & Hospital, Ramohalli Cross, Kumbalgodu, Karnataka, India.

3 Department of Conservative Dentistry & Endodontics, Annoor Dental College, Kerala, India.

**Corresponding author:** Dr. R Vinaya KUMAR, Flat 402, Sri Kiran Residency, No. 14, 4th Cross, 30th Main, Banashankari 3rd Stage, Bangalore-560085, Karnataka, India. Tel: 919844301016; E-mail: drrvinayakumar@gmail.com



**Fig 1** Defect following debridement.



**Fig 2** Placement of the PRF clot into the defect.

The procedure was explained to the patient in his own language and informed consent was obtained. The initial step of the treatment plan was to complete root canal therapy. The surgical protocol included a routine medical history followed by blood investigations. The procedure included the reflection of a full thickness mucoperiosteal flap by sulcular incision and two vertical relieving incisions. Debridement of the tissues at the defect site was followed by irrigation with sterile saline solution (Fig 1). Root resection and cold compaction was done at the apical end of the filling. The PRF clot was carefully placed till the entire cavity was filled (Fig 2). Wound closure was obtained with a 3-0 black silk suture and covered with a periodontal dressing. Analgesics, antibiotics and a 0.2% chlorhexidine mouthwash was prescribed for five days post surgery. The sutures were removed after 7 days. The patient was reviewed at regular intervals of 1 week, and 1, 3, 6 and 9 months. During the review, occlusal radiographs were taken. These follow-up visits included routine intraoral examinations and professional plaque control, if required. The case was evaluated clinically – for oedema, postoperative pain, signs of infection, untoward reaction, wound dehiscence – as well as radiographically.

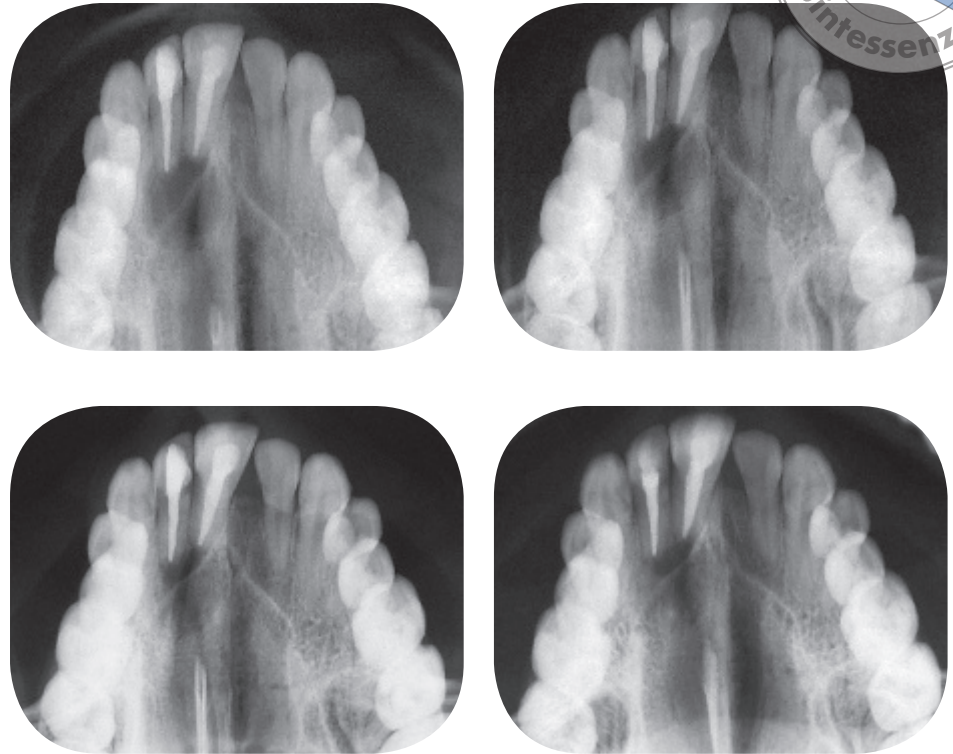
Clinically, there was moderate oedematous swelling 24 hours after surgery, which gradually subsided by the first week. The patient did not complain of any pain nor were there any signs of infection, untoward reaction or wound dehiscence. Radiographs showed bone regeneration with evidence of a trabecular pattern at the end of 9 months (Fig 3).

### Protocol for obtaining a PRF clot (Choukroun's Technique)

Whole blood is drawn into 9 ml blood collection tubes and is immediately centrifuged at 3,000 rpm for 10 minutes. Within a few minutes, the absence of anticoagulant allows activation of the majority of platelets contained in the sample to trigger a coagulation cascade. Fibrinogen is at first concentrated in the upper part of the tube, until the effect of the circulating thrombin transforms it into a fibrin network. The result is a fibrin clot containing the platelets located in the middle of the tube, between the red blood cell layer at the bottom and acellular plasma at the top. This clot is removed from the tube and the attached red blood cells scraped off and discarded.<sup>5</sup> It can be used directly as a clot or after compression as a strong membrane<sup>6</sup>. However, quick handling is the only way to obtain a clinically usable PRF clot<sup>7</sup>.

### Discussion

The success of endodontic therapy depends on complete periapical repair and regeneration. In a majority of cases, teeth with periapical lesions heal satisfactorily after nonsurgical endodontic intervention. However, there are cases with persisting symptoms and infection that require periradicular surgery in order to remove the pathological tissues, eliminate the source of irritation and promote healing. Research regarding the active use of growth factors present within the platelets started in the middle of the 20th century. These studies investigated the possibility of platelets



**Fig 3** Radiographs taken at baseline, 3, 6 and 9 months.

being used to modulate regeneration, and to repair and heal tissues<sup>4</sup>.

Platelet-rich fibrin has been widely used to accelerate soft and hard tissue healing<sup>5</sup>. It combines many healing and immunity promoters present in the initial blood harvest<sup>6</sup>.

PRF, unlike PRP, polymerises naturally and slowly during centrifugation, resulting in physiologic thrombin concentrations. This implies a very significant percentage of equilateral junctions, which allow the establishment of a fine and flexible fibrin network able to support cytokine enmeshment and cellular migration<sup>7</sup>.

This polymerisation mode also signifies an increased incorporation of the circulating cytokines in the fibrin meshes (intrinsic cytokines), implying an increased lifespan for these cytokines, because they will be released and used only at the time of initial cicatricial matrix remodeling (long term effect)<sup>8</sup>.

The clinical and radiographic criterion of von Arx and Kurt was used to evaluate the success of periapical surgery. The present case fell in the ‘improvement’ category as the bone regeneration was between 50% and 90%, while the pain and clinical scales were zero<sup>2</sup>.

In this case, PRF was used as a standalone treatment approach. However, some authors suggest mixing PRF with graft particles as they believe PRF functions as a ‘biological connector’ between the different elements of the graft while acting as a matrix favouring neo-angiogenesis, capture of stem cells and migration of osteoprogenitor cells to the center of the graft<sup>5</sup>. Further, a recent case report has shown that the combination of PRF and bioactive glass is an effective modality of regenerative treatment of radicular cysts<sup>9</sup>. This could be one of the reasons why we could not achieve complete regeneration of the defect by nine months.

The authors would like to conclude by stating that use of PRF as monotherapy for achieving periapical regeneration has shown promising results in the above case. As this platelet concentrate is entirely autologous in nature, it could be especially useful for defect resolution in patients who are unable to afford expensive regenerative therapies rather than leaving the defects to heal on their own. However, long-term comparative studies with adequate sample sizes comparing PRF with other regenerative treatment modalities are essential for a better perspective on this promising biomaterial.



## References

1. Martí-Bowen E, Peñarrocha M. An update in periapical surgery. *Med Oral Patol Oral Cir Bucal* 2006;11:E503–E509.
2. Peñarrocha Diago M, Ortega Sánchez B, García Mira B et al. Evaluation of healing criteria for success after periapical surgery. *Med Oral Patol Oral Cir Bucal* 2008;13:E143–E147.
3. von Arx T. Failed root canals: the case for apicoectomy (periradicular surgery). *J Oral Maxillofac Surg* 2005;63:832–837.
4. Vaishnavi C, Mohan B, Narayanan LL. Treatment of endodontically induced periapical lesions using hydroxyapatite, platelet-rich plasma, and a combination of both: An in vivo study. *J Conserv Dent* 2011;14:140–146.
5. Toffler M, Toscano N, Holtzclaw D, et al. Introducing Choukroun's platelet rich fibrin (PRF) to the reconstructive surgery milieu. *Journal Implant Adv Clin Dent* 2009;1:21–31.
6. Dohan Ehrenfest DM, Del Corso M, Diss A, et al. Three-dimensional architecture and cell composition of a Choukroun's platelet-rich fibrin clot and membrane. *J Periodontol* 2010;81:546–555.
7. Dohan DM, Choukroun J, Diss A, et al. Platelet-rich fibrin (PRF): A second-generation platelet concentrate. Part I: Technological concepts and evolution. *Oral Surg Oral Med Oral Pathol Oral Radiol Endod* 2006;101:e37–e44.
8. Dohan DM, Choukroun J, Diss A, et al. Platelet-rich fibrin (PRF): A second-generation platelet concentrate. Part II: Platelet-related biologic features. *Oral Surg Oral Med Oral Pathol Oral Radiol Endod* 2006;101:e45–e50.
9. Zhao JH, Tsai CH, Chang YC. Management of radicular cysts using platelet-rich fibrin and bioactive glass: A report of two cases. *J Formosan Med Assoc* 2012;doi:10.1016/j.jfma.2011.09.027.

