

A New Technique for Minimally Invasive Maxillary Lateral Sinus Augmentation: a Case Report

Xiu Lian HU¹, Xian ZHOU¹, Jian Hui LI¹, Ye LIN¹

Numerous techniques are described for lateral sinus augmentation, in order to expand bone volume, either by a crestal or lateral approach. A successful surgical procedure is determined by a number of factors. It is reported that different techniques for sinus augmentation have a high percentage of success, but presents a number of intraoperative and postoperative complications such as the Schneiderian membrane perforation and a long operating time. To manage the problem of the insufficient bone height in the posterior maxilla, various bone-grafting materials were applied using different techniques and instruments to elevate the sinus membrane and fill the subsinus cavity thereafter. The article aimed to describe a minimally invasive technique, using a special design bur to wear out the lateral bone safely and elevate the sinus membrane with sophisticated separators. Platelet-rich fibrin (PRF) and decalcified bone allograft was used as grafting material to enhance bone healing. This new technique for the sinus lateral wall osteotomy minimised the incidence of intraoperative and postoperative complications and the mixed use of PRF with decalcified bone allograft showing a satisfactory efficacy.

Key words: decalcified bone allograft, implant, lateral sinus augmentation, minimally invasive, platelet-rich fibrin

Chin J Dent Res 2015;18(4):241–245; doi: 10.3290/j.cjdr.a35149

The edentulous posterior maxillae generally provide a limited amount of bone volume owing to an atrophy of the alveolar bone ridge and pneumatization of the maxillary sinus¹. Numerous techniques have been developed and applied in the sinus augmentation procedure, in order to increase bone volume of the posterior atrophic maxilla, either by a crestal or lateral approach²⁻⁴. Previous studies of sinus augmentation reported a high percentage of success, but also presents a number of intraoperative and postoperative complications, such as membrane perforation, hemorrhage, fracture of the residual alveolar ridge, graft loss, infection, etc^{5,6}. The most frequent one is the Schneiderian membrane perforation, which in most cases occurred during the use of rotary instruments for sinus wall osteotomy, before lift-

ing the membrane. Over the last several decades, numerous studies have reported a variety of surgical techniques to elevate the maxillary sinus floor safely and the quality of grafting materials have been evaluated^{7,8}. A recently published review concluded that the amount of new bone formed was comparable when anorganic bovine bone or anorganic bovine bone together with autologous bone was used as the graft material⁹. However, current trends in oral surgery are directed towards enhancing the healing process in surgical wounds by manipulating the wound microenvironment. Blood clots per se have been shown to contain endogenous growth factors and therefore have the potential to stimulate bone formation¹⁰. Platelet-rich fibrin (PRF) is extracted from blood clot and contains up to 95% of platelets trapped within fibrin mesh, which release the growth factors during a certain period of time¹¹. A high concentration of platelets is an autonomous source of growth factors, which are responsible for the high regenerative potentiality in soft and hard oral tissues. Our previous studies showed that anorganic bovine bone and PRF used together as grafting materials during sinus lift can promote bone regen-

¹ Department of Oral Implantology, Peking University School and Hospital of Stomatology, Beijing, P.R. China

Corresponding author: Dr Ye LIN, Department of Oral Implantology, Peking University School and Hospital of Stomatology, #22 Zhongguancun South Avenue, Haidian District, Beijing 100081, P.R. China. Tel: 86-10-82195344; Fax: 86-10-62173402. Email: yorcklin@263.net

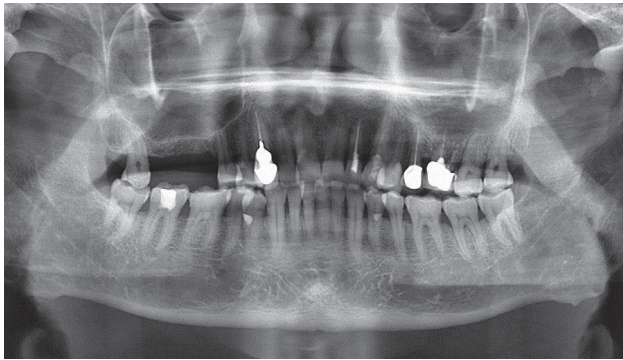


Fig 1 During panoramic tomography examination, the available bone height in the molar region was 3.8 mm.

eration and shorten the healing period¹². In this article we aimed to report a minimally invasive new technique to grind the sinus lateral wall safely and we used PRF and anorganic bovine bone to enhance bone healing.

Case report

A 74-year-old male patient presented with the chief complaint of difficulty in chewing from the right side because of loss of teeth in the right upper back tooth region. On oral examination, the right upper first molar and second molar were missing. On radiographic examination, the available bone height in the molar region was

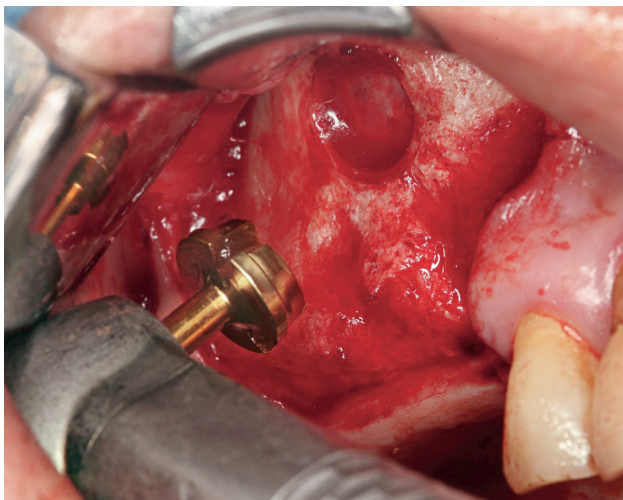


Fig 2 The lateral bone window was prepared with a sophisticated drill to avoid perforating the sinus membrane. The drill shape was conical in order to control the drilling depth and to grind the bone safely.

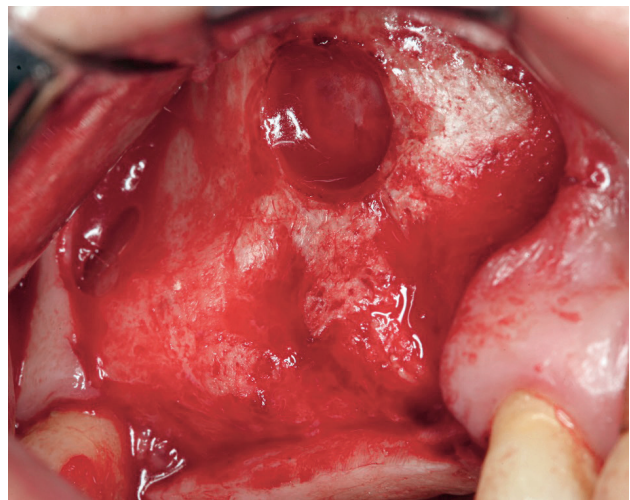


Fig 3 After preparing the window there was a thin layer of bone on the membrane that protected the membrane from tearing.

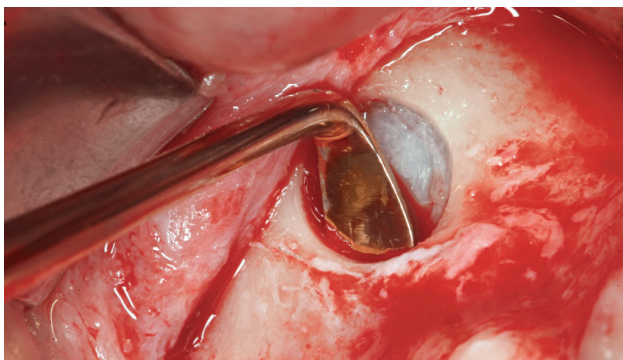


Fig 4 The 'L'-shaped elevator was used to detach the sinus membrane from the lower part of the sinus lateral wall.

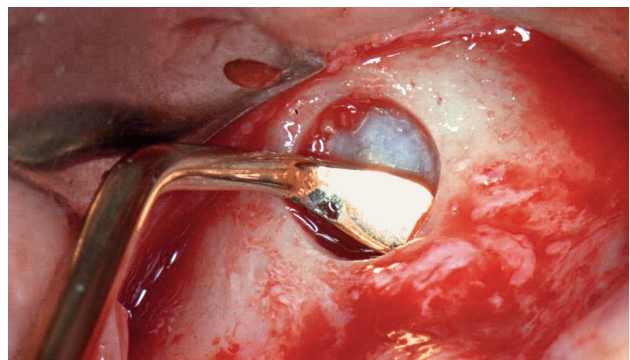


Fig 5 The small-head elevator was used to detach the sinus membrane from the mesial part of the sinus lateral wall.

3.8 mm (Fig 1). In this case, criteria, such as the position of the implants, preexisting tooth form and position, its relation with the opposing arch, soft tissue anatomy, maxillary sinus anatomy and bone dimensions were considered. After thorough oral and radiographic examination, two-stage surgery was planned. It was decided that the sinus membrane would be lifted up with a lateral approach using a special design bur and that the implants would be inserted simultaneously. Two Nobel Biocare Replace implants (Nobel Biocare, Goteborg, Sweden) of 11.5 mm length and 4 mm diameter were selected. The patient received a detailed explanation regarding the treatment plan and signed an informed consent form.

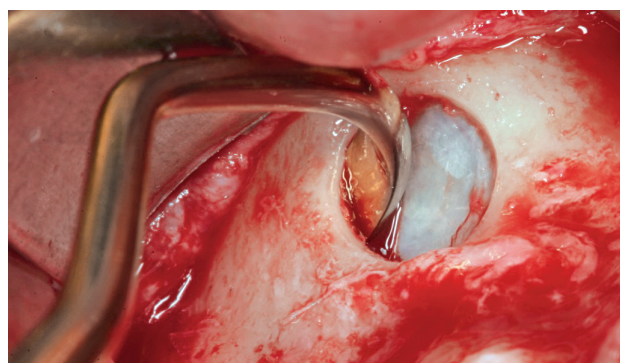


Fig 6 The 'Big bend'-shaped elevator was used to detach the sinus membrane from the distal and the deep part of the sinus lateral wall.

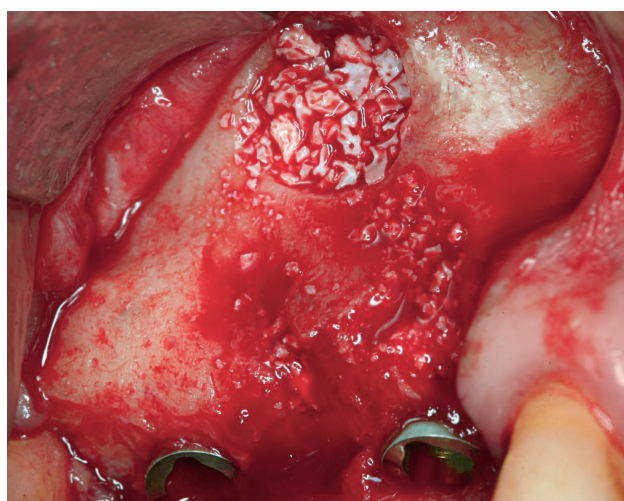


Fig 7 A mix of autologous platelet-rich fibrin and anorganic bovine bone was grafted. The buccal bone defect was also augmented.

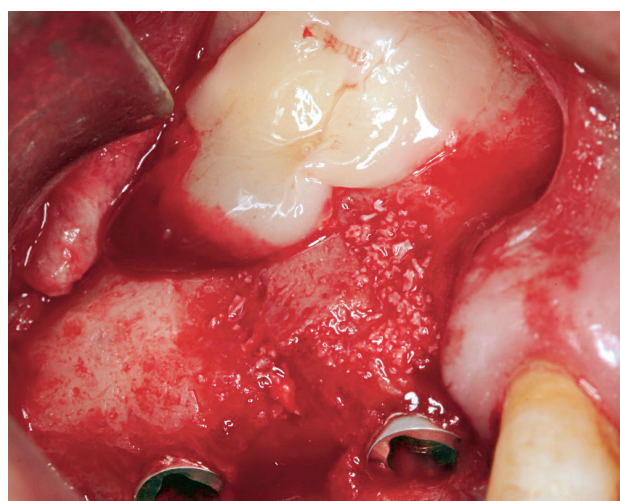

Fig 8 PRF was prepared as a membrane to cover the bone window, in order to enhance bone healing.

The treatment was phased out in the following manner:

- The operation was performed under local anesthesia using Articaine Hydrochloride with 1:100000 Adrenalin (Merignac Cedex, Merignac, France). An incision on the alveolar crest extending to the mesial part of the edentulous area was made and a mucoperiosteal flap was raised to expose the surgical site.
- The lateral bone window was prepared with a sophisticated drill (SLA Kit, Neobiotech, Seoul, South Korea) to avoid perforating the sinus membrane. There was a thin layer of bone on the membrane that protected the membrane from tearing and the drill shape was conical allowing control of the drilling depth (Figs 2 and 3).

Three small head-elevators with different angles (SLA Kit, Neobiotech, South Korea) were used to elevate the sinus membrane atraumatically (Figs 4 to 6). The sinus membrane was carefully reflected from the sinus floor to achieve sufficient space for the bone substitute. When no visible perforation was observed, the space was filled with a mix of autologous PRF and anorganic bovine bone (Bio-Oss, Ø1-2 mm, Geistlich Pharma AG, Wolhusen, Switzerland), and PRF was prepared as a membrane to cover the bone window and the elevated sinus membrane, to enhance bone healing and protect the Schneiderian membrane from tearing (Figs 7 and 8). The flap was repositioned and sutured with the 4/0 resorbable suture (Vicryl 4-0, Johnson & Johnson Medical, USA).

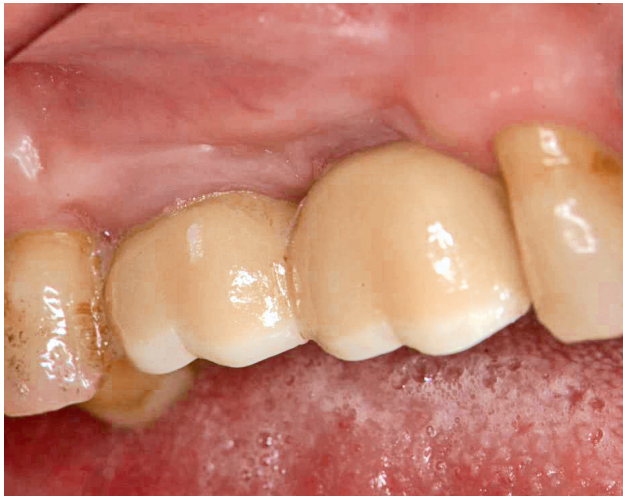

Fig 9 All ceramic Procerea crowns were delivered and after 43 months follow-up peri-implant gingiva was healthy.

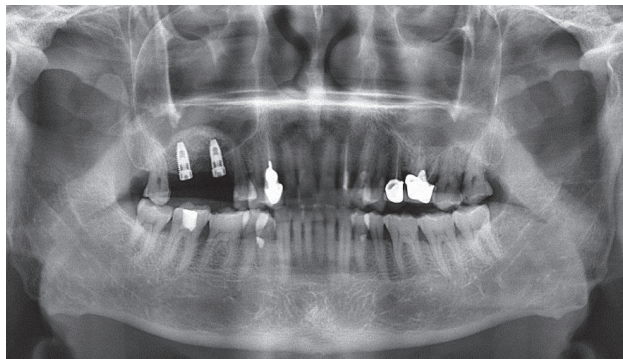


Fig 10 During panoramic tomography examination, right after the operation, the sinus membrane was elevated like a dome shape and implants were surrounded by the bone graft materials.

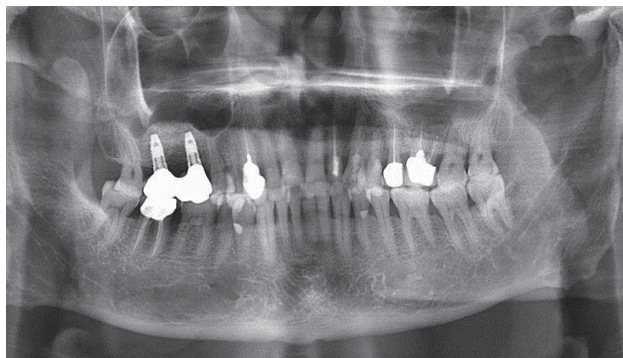


Fig 11 One year after restoration, the peri-implant marginal bone was stable and the grafted bone material was more compact.

After a healing time of 6 months, second stage surgery was performed and implants were restored with all ceramic crowns (Procerea, Nobel Biocare, Goteborg, Sweden) (Fig 9). The patient was instructed about the maintenance of oral hygiene by means of dental floss, an interdental brush and mouthwash. The patient was called upon for recall visits annually. Follow-up (3 years and 7 months) after 43 months was uneventful (Figs 10 to 12).

Discussion

With the advancement in the field of implant dentistry, implant- supported prostheses are no longer a big challenge. When the quantity and quality of the alveolar ridge are adequate and satisfactory, the implant placement becomes an easy task, but when alveolar ridges are severely resorbed, the bone volume must be augmented before implants may be placed. Placement of implants is of more concern in posterior maxilla because of the presence of the maxillary sinus. Due to sinus pneumatolysis and bone resorption, it is mandatory to lift up the sinus membrane and graft it to increase the bone height before implant placement. Many techniques have been demonstrated using different instruments for sinus elevation. Intraoperative tearing or perforation of the sinus membrane is the most common complication and the reported incidence in the literature ranges from 7% to 56%¹³. This article describes a technique that used a sophisticated drill and fine elevators to lift up the sinus membrane safely and reliably. The advantage of this method is that the procedure is less complex, less invasive and has a shorter healing and waiting period.

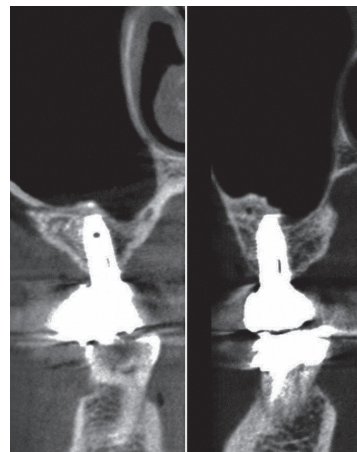


Fig 12 After 43 months of follow-up, peri-implant marginal bone and sinus bone graft was stable on the CBCT.

Autogenous bone has long been considered as the best option among all grafting materials. Scientific-based evidence shows that bone formation occurs through the multiple pathways of osteoinduction, osteoconduction and osteogenesis, when a viable autogenous graft is placed in an appropriate aseptic environment with sufficient blood supply. Therefore, autogenous bone was initially considered as the first choice of grafting material for maxillary sinus augmentation. However, the use of a supplemental autogenous bone donor site may be accompanied by transient or permanent donor site morbidity. Donor site morbidity is often considered a drawback when contemplating the use of autogenous bone for implant dentistry¹⁴. Currently, additional evidence-based reviews have reported on the efficacy of all forms of graft material, noting that allografts, alloplasts and xenografts can be effective in indicated clinical situations¹⁵. In this case, we use PRF together with xenograft to enhance wound healing, to protect the sinus membrane from tearing, to stimulate periosteum-like regenerative potential of the membrane and to maintain the implant in its position. Our previous study showed that PRF can act as a biological connector between bone graft particles to improve graft stabilisation. A combination of bone grafts and PRF enhance bone density and provide faster healing than using xenograft grafts alone¹². In addition, PRF prevents early invagination of undesired cells thus acting like a viable barrier between desired and undesired cells. Thus, it prevents fibroblasts growing into the bone window.

Conflicts of interest

The authors reported no conflicts of interest related to this study.

Author contribution

Dr Xiulian Hu for the overall design of the case and for completing the surgical and oral restoration procedures; Miss Xian Zhou for collecting the data, recording the follow-ups and writing the paper; Dr Jianhui Li for the design of the oral restoration process and Prof Ye Lin for the design of the surgical procedures.

References

- Asai S, Shimizu Y, Ooya K. Maxillary sinus augmentation model in rabbits: effect of occluded nasal ostium on new bone formation. *Clin Oral Implants Res* 2002;13:405–409.
- Soltan M, Smiler D, Ghostine M, Prasad HS, Rohrer MD. The crestal approach: antral membrane elevation via a post graft. *Implant Dent* 2011;20:e53–e60.
- Pariente L, Dada K, Daas M. Mini-lateral windows for minimally invasive maxillary sinus augmentation: case series of a new technique. *Implant Dent* 2014;23:371–377.
- Lee JE, Jin SH, Ko Y, Park JB. Evaluation of anatomical considerations in the posterior maxillae for sinus augmentation. *World J Clin Cases* 2014;2:683–688.
- Zijdeveld SA, van den Bergh JP, Schulten EA, ten Bruggenkate CM. Anatomical and surgical findings and complications in 100 consecutive maxillary sinus floor elevation procedures. *J Oral Maxillofac Surg* 2008;66:1426–1438.
- Kazancioglu HO, Tek M, Ezirganli S, Mihmanli A. Comparison of a novel trephine drill with conventional rotary instruments for maxillary sinus floor elevation. *Int J Oral Maxillofac Implants* 2013;28:1201–1206.
- Duttenhoefer F, Souren C, Menne D, Emmerich D, Schön R, Sauerbier S. Long-term survival of dental implants placed in the grafted maxillary sinus: systematic review and meta-analysis of treatment modalities. *PLoS One* 2013;8:e75357.
- Rickert D, Slater JJ, Meijer HJ, Vissink A, Raghoobar GM. Maxillary sinus lift with solely autogenous bone compared to a combination of autogenous bone and growth factors or (solely) bone substitutes. A systematic review. *Int J Oral Maxillofac Surgery* 2012;41:160–167.
- Handschel J, Simonowska M, Naujoks C, et al. A histomorphometric meta-analysis of sinus elevation with various grafting materials. *Head Face Med* 2009;5:12.
- Dahlin C, Linde A, Gottlow J, Nyman S. Healing of bone defects by guided tissue regeneration. *Plast Reconstr Surg* 1988;81:672–676.
- He L, Lin Y, Hu X, Zhang Y, Wu H. A comparative study of platelet-rich fibrin (PRF) and platelet-rich plasma (PRP) on the effect of proliferation and differentiation of rat osteoblasts in vitro. *Oral Surg Oral Med Oral Pathol Oral Radiol Endod* 2009;108:707–713.
- Zhang Y, Tangl S, Huber CD, Lin Y, Qiu L, Rausch-Fan X. Effects of Choukroun's platelet-rich fibrin on bone regeneration in combination with deproteinized bovine bone mineral in maxillary sinus augmentation: a histological and histomorphometric study. *J Craniomaxillofac Surg* 2012;40:321–328.
- Barone A, Santini S, Sbordone L, Crespi R, Covani U. A clinical study of the outcomes and complications associated with maxillary sinus augmentation. *Int J Oral Maxillofac Implants* 2006;21:81–85.
- Nkenke E, Stelzle F. Clinical outcomes of sinus floor augmentation for implant placement using autogenous bone or bone substitutes: a systematic review. *Clin Oral Implants Res* 2009;20(Suppl 4):124–133.
- Del Fabbro M, Wallace SS, Testori T. Long-term implant survival in the grafted maxillary sinus: a systematic review. *Int J Periodontics Restorative Dent* 2013;33:773–783.

The Chinese Journal of Dental Research

The Official Journal of the
Chinese Stomatological Association (CSA)

GUIDELINES FOR AUTHORS

The *Chinese Journal of Dental Research* is a peer-reviewed general dental journal published in English by the Chinese Stomatological Association. The Journal publishes original articles, short communications, invited reviews, and case reports. Manuscripts are welcome from any part of the world. The Journal is currently published quarterly and distributed internationally by Quintessence Publishing Co Ltd.

All authors are asked to adhere to the following guidelines.

Manuscript submission

ScholarOne Manuscripts for The Chinese Journal of Dental Research (CJDR) has been launched.

To submit your outstanding research results more quickly, please visit: <http://mc03.manuscriptcentral.com/cjdr>

Any questions, please contact:

#22 Zhongguancun Nandajie, Haidian District, Beijing 100081, People's Republic of China. E-mail: editor@cjdrcsa.com;
Tel: 86-10-82195785; Fax: 86-10-62173402.

Submitted manuscripts must be unpublished original papers that are not under consideration for publication elsewhere. Submissions that have been published with essentially the same content will not be considered. This restriction does not apply to results published as an abstract. The submission of a manuscript by the authors means that the authors automatically agree to assign exclusive licence to the copyright to Quintessence Publishing Co Ltd if and when the manuscript is accepted for publication.

Manuscripts must be accompanied by a letter from all authors or from one author on behalf of all the authors containing a statement that the manuscript has been read and approved by all the authors and the criteria for authorship have been met. It should also contain the following statement: "The attached (enclosed) paper entitled ... has not been published and is not being submitted for publication, in whole or in part, elsewhere".

Manuscripts that reveal a lack of proper ethical consideration for human subjects or experimental animals will not be accepted for publication. The Journal endorses the Recommendations from the Declaration of Helsinki.

Format of Papers

Preparation of manuscripts

The manuscript should be written clearly and concisely and be double-spaced on 21 x 29 cm white paper with at least 2.5 cm margin all around. All pages should be numbered, beginning from section of title page, and followed by abstract, introduction, materials and methods, results, discussion, acknowledgements, references, figure legends and figures/tables. Non-standard abbreviations should be defined when first used in the text. Use a standard font such as Times New Roman or Arial to avoid misrepresentation of your data on different computers that do not have the unusual or foreign language fonts. For units, the Journal recommends the use of the International System of Units (SI Units). For authors whose native language is not English, the Journal strongly recommends improving the English in the manuscript by consulting an English-speaking scientist before submission.

Title page should include: full title (a brief declarative statement of the major findings of the research), full names of authors, professional affiliations and complete postal address, telephone and fax number, and email address of the corresponding author. If the work was supported by a grant, indicate the name of the supporting organisation and the grant number.

Abstract and keywords: 250 words presented in a concise form and including the purpose, general methods, findings, and conclusions of the research described in the paper. A list of 5 keywords or short phrases (a few words per phrase) suitable for indexing should be typed at the bottom of the abstract page. Avoid vague or overly general terms. If necessary, the keywords will be adjusted to the standards of the Journal by the editors without consulting the authors.

Introduction: should begin with a brief introduction of background related to the research and should be as concise as possible. The rationale of the study should be stated.

Materials and Methods: should be described clearly and referenced in sufficient detail. Description should be such that the reader can judge the accuracy, reproducibility, reliability, etc. of the work.

Results: should present the experimental data in tables and figures with suitable descriptions and avoid extended discussions of its relative significance.

Discussion: should focus on the interpretation and significance of the findings with concise objective comments. Speculation is to be based on data only. The text should be written with a logical connection between the introduction and conclusions.

Acknowledgements: should only recognise individuals who provided assistance to the project.

References: should be cited in the text using superscript numbers and typed in numerical order following a style below:

1. Sorensen JA, Engleman MT, Torres TJ, Avera SP. Shear bond strength of composite resin to porcelain. *Int J Prosthodont* 1991;4:17-23.
2. Renner RP, Boucher LJ. Removable Particle Dentures. Chicago: Quintessence, 1987:24-30.
3. White GE, Johson A van Noort R, Northeast SE, Winstanley B. The quality of cast metal ceramic crowns made for the NHS [abstract 48]. *J Dent Res* 1990;69(special issue):960.
4. Jones DW. The strength and strengthening mechanisms of dental ceramics. In: McLean JW (ed). *Dental ceramics: Proceedings of the First International Symposium on Ceramics*. Chicago: Quintessence, 1983:83-41.
5. Rosenstiel S. The Marginal Reproduction of Two Elasto meric Impression Materials [Master's thesis]. Indianapolis: Indiana University, 1997.

Figures and Tables: should be numbered consecutively with Arabic numerals, with each one displayed on a separate page. Photographs should be of excellent quality with a width of 8 cm or 17 cm. All figures and tables should be cited in the text. Please refer to a current volume of this Journal for general guidance.

Legends for all figures, including charts and graphs, must be typed together on a separate page and should be understandable without reference to the text, including a title highlighting the key results and a key for any symbols or abbreviations used in the figure.

Case reports

Authors should describe one to three patients or a single family. The text is limited to no more than 2500 words, and up to 15 references.

Revised Manuscripts

All revisions must be accompanied by a cover letter to the Editor. The letter must detail on a point-by-point basis the contributors' disposition of each of the referees' comments, and certify that all contributors approve of the revised content.