

# Assessing Maxillary Molar Furcation Involvement by Cone Beam Computed Tomography

Jie ZHU<sup>1,2</sup>, Xiang Ying OUYANG<sup>1</sup>

**Objective:** To evaluate the reproducibility of four parameters for quantitatively assessing maxillary molar furcation involvement (FI) by cone beam computed tomography (CBCT).

**Methods:** Thirty-nine sites with degree II FI, classified by probing of 21 maxillary molars, were investigated. Degrees of FI in these sites were assessed based on CBCT data. In these samples, four parameters for quantitatively assessing FI in CBCT images were measured. The parameters included horizontal bone loss at furcation entrance level (HBL), maximum HBL (HBL-max), maximum vertical bone loss (VBL-max) and root trunk length (RT). The reproducibility of the measurements was evaluated.

**Results:** Amongst the 39 degree II FI classified by probing, only 17.9% were confirmed by CBCT. The other 46.2% were 'through and through' defects, 15.4% were fused roots and 20.5% were degree I FI in the CBCT image. The intraobserver repeatability for all four parameters was high, with intraclass correlation coefficients (ICC) of 0.960 for HBL, 0.992 for HBL-max, 0.987 for VBL-max and 0.983 for RT. The ICCs for two observers was also high (ICCs: 0.873 to 0.947). The parameters and related methods of measurements proposed in the study showed high reproducibility. CBCT images provided more details in assessing maxillary molar FI.

**Conclusion:** The parameters and related methods of measurements developed in this study showed high reproducibility. CBCT images provide more details in assessing maxillary molar FI.

**Key words:** cone-beam computed tomography, furcation involvement, linear measurement, maxillary molars

*Chin J Dent Res* 2016;19(3):145–151; doi: 10.3290/j.cjdr.a36679

Furcation involvement (FI) is a lesion in periodontitis-affected furcations of multi-rooted teeth. The severity and extent of FI influence the tooth's prognosis and the treatment plan<sup>1</sup>. Generally, class I FI can be well managed with routine periodontal procedures. Class II

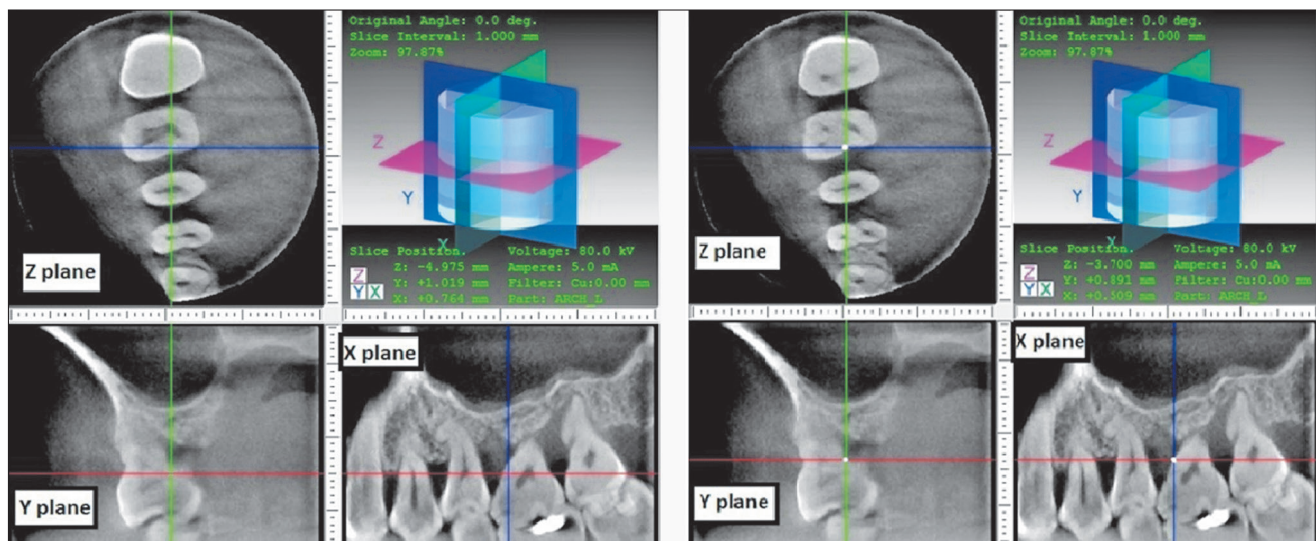
FI presents more favourable outcomes by regenerative therapy, and class III furcations require more extensive therapy such as tunneling, root amputation, hemisection or extraction. Therefore, it is important to detect the details of furcation lesions before therapy.

Conventional examination of FI includes probing and periapical radiographs. Besides the vertical attachment loss, horizontal attachment loss is another feature of FI. Naber's probe has been recommended for the horizontal attachment loss measurement<sup>2</sup>. However, the reliability of probing is influenced by many factors, such as the inflammatory status, probing force, shape of the probe, training of the operator, the length of root trunk and the anatomy of the root<sup>3</sup>. Periapical radiographs could provide evidence of bone loss in the furcation area. The radiographic appearance of mandibular

1 Department of Periodontology, Peking University School and Hospital of Stomatology, National Engineering Laboratory for Digital and Material Technology of Stomatology, Beijing Key Laboratory of Digital Stomatology, Beijing, P.R. China.

2 Department of Stomatology, Peking University International Hospital, Beijing, P.R. China.

**Corresponding author:** Dr Xiang Ying OUYANG, Department of Periodontology, Peking University School and Hospital of Stomatology, 22# Zhongguancun South Avenue, HaiDian District, Beijing 100081, P.R. China. Tel: 86-10-82195531; Fax: 86-10-62173402. Email: kqouyangxy@126.com



**Fig 1** Determination of the mesiopalatal FE of tooth 16 (right maxillary first molar). Left panels: Sectional CBCT images in the furcation area of 16 (right maxillary first molar). A horizontal image of the mesial site of 16 in the Z plane (upper left corner) with a smooth outline. Right panels: Apical image in the Z plane of the same tooth. In this horizontal image, the tooth outline in the Z plane appeared as a concave point (white point); this point was considered as the landmark of the FE. The crossing point of the axis was moved to the concave point, then the Y plane and X plane showed the sectional image of the FE, named the Y plane of FE (lower left corner) and the X plane of FE (lower right corner graphic).

molar FI includes a wider space for the periodontal ligament or a lower density (or lucency area) in the furcation area. For maxillary molars, the FI in radiographs is not evident because of the image overlap of the palatal root and alveolar bone. It was reported that true furcation lesions had always been underestimated in periapical radiographs due to the inherent shortcomings of two-dimensional imaging and the interference of image overlap<sup>4-6</sup>. Therefore, probing and periapical radiographs provide information about FI inadequately, especially in maxillary molars.

Cone beam computed tomography (CBCT) was introduced to dentistry in the late 1990s and soon became widely used. Compared with conventional spiral computed tomography, CBCT has markedly reduced radiation exposure and costs, and provides higher spatial resolution. The accuracy of CBCT for dental maxillofacial bone tissue has been confirmed by studies<sup>7-12</sup>. Several studies have reported the application of CBCT in the assessment of FI. However, few studies have focused on the quantitative measurements that reflect the extent of FI using CBCT. The purpose of the present study was to introduce methods of linear quantitative measurement and classification concerning maxillary molar FI in CBCT imaging, and to evaluate the reproducibility of these measurements.

## Materials and methods

### Subjects

The study population came from patients at the Department of Periodontology, Peking University School and Hospital of Stomatology, Beijing, China. Eleven patients with maxillary molars classified as degree II FI were recruited. According to Glickman, degree II FI means the bone is destroyed on one or more aspect of the furcation, but a portion of the alveolar bone and periodontal ligament remains intact, permitting only partial penetration of the probe into the furcation<sup>13</sup>. Teeth with crowns, bridges or amalgam fillings were excluded. A total of 21 maxillary molars (12 first molars and nine second molars) with 39 (nine buccal sites, 10 mesiopalatal sites and 20 distopalatal sites) degree II FI were included. All subjects were thoroughly informed about the research and the methods applied. The written consent was signed. The study was independently reviewed and approved by the institutional ethics board of Peking University School and Hospital of Stomatology.

### Collection of CBCT data

CBCT was performed in the posterior maxillary area using a high-resolution imaging system (3D Accuitemo 60, XYZ Slice View Tomograph; J. Morita, Kyoto, Japan). Cylindrical volumes of  $4 \times 4$  to  $6 \times 6$  cm, with a setting in the range of 80 kV, 5.0 to 6.3 mA and a voxel size of  $0.125 \times 0.125 \times 0.125$  mm were used. The sagittal plane (X plane) and coronal plane (Y plane) were adjusted to be parallel with the long axis of the tooth, and the horizontal plane (Z plane) to be parallel with the occlusal plane. Reconstruction was carried out with a slice thickness setting of 1 mm. The measurements achieved by the software I-Dixel-3DX (J. Morita) were made to the nearest 0.01 mm. All images were analysed twice by the same person, with a time interval of more than 1 week on the same monitor under standard conditions.

### Determination of furcation entrance in CBCT images

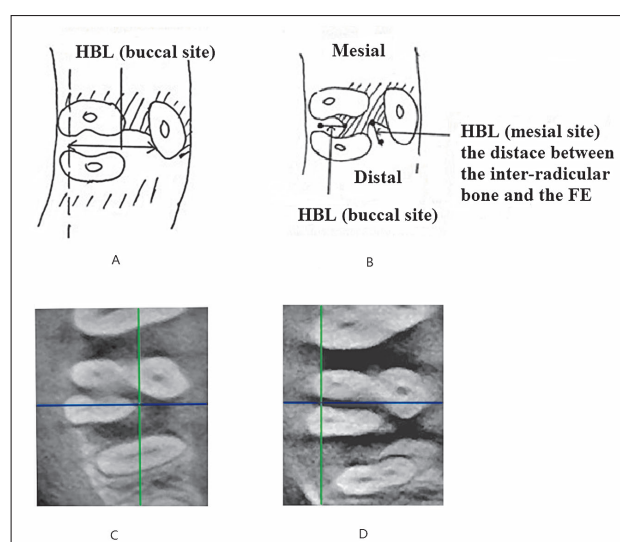
The sequential images of the furcation area in the horizontal plane (Z plane) were observed continuously in an occlusal-to-apical direction. When a concave curve appeared in the outline of the tooth from a smooth configuration in the horizontal images (left four panels in Fig 1), the concave point was considered as the reference point of the furcation entrance (FE). The crossing point of the axis was moved to the concave point, then the Y plane and X plane showed the sectional image of the FE (right panels in Fig 1), named the Y plane of the FE and the X plane of the FE. Most measurements of FI were performed in these two planes.

### Classification of FI on CBCT

FI degrees were classified in the horizontal plane (Z plane) and were graded according to Glickman's classification system: degree 0 for no bone loss in the furcation area; degree I for a small amount of vertical bone loss, but no horizontal bone loss in the furcation area; degree II for the existence of horizontal bone loss but no 'through and through' destruction; and degree III for horizontal 'through and through' destruction in the furcation area.

### Parameters of FI measured on CBCT

Four different FI parameters were measured using CBCT images. Firstly, horizontal bone loss at the FE level (HBL) was measured as the distance between the interradicular bone and the FE. The measurement was



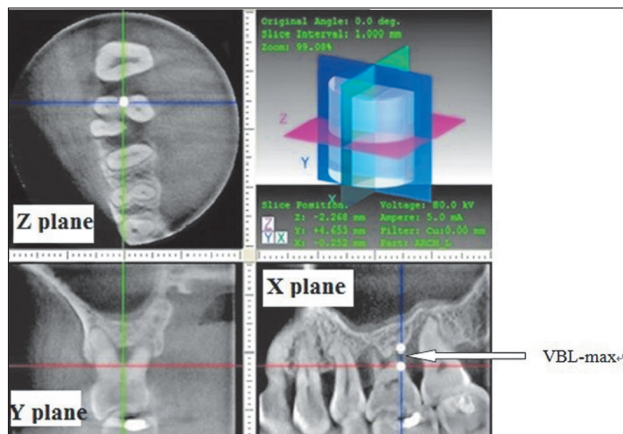
**Fig 2** Measurements of HBL. A) HBL at the FE level measured in the Z plane; B) HBL at the FE level for degree III FI in the buccal sites. HBL was the distance between the FE and the palatal root; C) Corresponding images in the Z plane of the CBCT for Fig 2.1. The crossing point of axes was the FE; D) Corresponding images in the Z plane of CBCT for Fig 2.2. The crossing point of axes was the FE.

performed in the Z plane in which the roots had become totally separated (Fig 2A). When the FI was shown as a 'through and through' defect (degree III) in the CBCT images, mesiopalatal and distopalatal sites were not measurable. For buccal sites, HBL was the horizontal distance between FE and the palatal root (Fig 2B).

Secondly, the maximum distance of HBL in the furcation area (HBL-max) was measured as the horizontal distance between the FE and the deepest defect. The measuring plane was the Z plane in which the deepest horizontal bone loss could be observed. Mesiopalatal and distopalatal sites were not measurable when the FI was a 'through and through' defect (degree III). For buccal sites, HBL-max was the horizontal distance between the FE and the palatal root in the measuring plane.

Thirdly, the maximum distance of vertical bone loss in the furcation area (VBL-max) was measured as the vertical distance between the most apical point of the bone defect and the roof of furcation, which was measured in the X plane (for mesiopalatal and distopalatal furcation) or the Y plane (for buccal furcation) of the FE (Fig 3). Determination of the X/Y plane of the FE is shown in Figure 1.

Fourthly, the root trunk length (RT) was measured as the vertical distance between the cemento-enamel junc-



**Fig 3** VBL-max of distal furcation: the distance between the two white points on the X plane (lower right).

tion (CEJ) and the FE. Measurements were done in the X plane (for buccal sites) and the Y plane (for mesial and distal sites) of the FE.

All the measurements were repeated twice by observer 1 with a time interval of more than 1 week. Eleven sites which were measurable for HBL were chosen to be measured by another trained observer. All four parameters in the 11 sites were recorded.

#### Statistical analysis

The reproducibility of double measurements for observer 1 and the measurements of the two observers for all the measurements in the CBCT images was evaluated by an intraclass correlation coefficient (ICC). ICC is an index that reflects the relative similarity of quantities that share the same observational units of measurements. The RT in different sites was analysed by one-way ANOVA and Tukey HSD analysis at a 95% confidence level, a  $P$  value of  $\leq 0.05$  was used for the statistical analysis.

## Results

#### Classification of FI on CBCT versus probing assessment

In the 39 FI classified as degree II by clinical probing, 17.9% (seven sites) were confirmed as degree II by CBCT data (Table 1). Distopalatal sites showed the lowest coordinate rate of 10% between clinical and CBCT assessments. In addition, 20.5% (eight sites) and 15.4% (six sites) exhibited no HBL or fusion roots, respectively, in CBCT images. The remaining 46.2% (18 sites) had 'through and through' defects.

#### The reproducibility of the four proposed parameters for the FI measured on CBCT

The double measurements of HBL, HBL-max, VBL-max and RT are shown in Table 2. The ICCs were 0.960 to 0.992.

For degree III FI in buccal sites, HBL and HBL-max were  $4.80 \pm 0.34$  mm and  $6.81 \pm 1.59$  mm, respectively.

The measurements of the 11 sites chosen to be measured by observer 2 was compared with observer 1, which are shown in Table 3. The ICCs were 0.873 to 0.947.

#### The length of the RT in CBCT images

Table 4 shows the length of the RT of all 21 molars. Mesial and distal RTs were significantly longer than buccal RTs; however, no significant differences were found between mesial and distal RTs. There was no statistical difference in the first and second maxillary molars, either.

## Discussion

CBCT is widely used in the dental maxillofacial area. However, FI-related parameters and their measuring methods are used less often. The present study proposed and evaluated four parameters representing the extent and severity of FI in maxillary molars, including HBL, HBL-max, VBL-max and RT. The measuring methods of these parameters are described in this paper. As a result, all of these four parameters had high reproducibility. In addition, the criteria of FI classification on CBCT have also been provided. These parameters and methods reveal details of maxillary molar furcation lesions, which could help clinicians to make accurate diagnoses and effective treatment plans for patients.

The reference point of the furcation entrance (FE) was the first to be identified when the parameters were measured. The present study described how to identify the landmark of the FE in the maxillary molar in CBCT images. Zhong et al<sup>14</sup> described the FE determination in mandibular molars. The author compared CBCT measurements with direct probing in artificial degree II FI of mandibular molars in a dry skull. They defined the landmark of the FE as the turning point of the crown in the coronal plane of the furcation area. However, the turning point could not be observed in maxillary molars because the anatomical morphology of the crown was different from that of mandibular molars. Qiao et al<sup>15</sup> compared FI measurements of

**Table 1** Comparison of clinical and CBCT assessments.

Location	CBCT assessments				
	1	2	3	Fused roots	Total
Buccal	0 (0%)	3 (33.3%)*	5 (55.6%)	1 (11.1%)	9 (100%)
Distopalatal	7 (35.0%)	2 (10.0%)*	6 (30.0%)	5 (25.0%)	20 (100%)
Mesiopalatal	1 (10.0%)	2 (20.0%)*	7 (70.0%)	0 (0%)	10 (100%)
Total	8 (20.5%)	7 (17.9%)*	18 (46.2%)	6 (15.4%)	39 (100%)

\* CBCT results revealed the same degree as clinical assessments (degree II)

**Table 2** Reproducibility of the double CBCT measurements for observer 1.

	Measurements 1 (mean ± SD) (mm)	Measurements 2 (mean ± SD) (mm)	ICC
HBL (n = 11) <sup>a</sup>	3.12 ± 1.68	2.98 ± 1.42	0.960
HBL-max (n = 11) <sup>a</sup>	4.06 ± 2.53	3.95 ± 2.52	0.992
VBL-max (n = 33) <sup>b</sup>	3.97 ± 2.84	4.17 ± 2.80	0.987
RT (n = 30) <sup>c</sup>	3.74 ± 1.25	3.64 ± 1.20	0.983

HBL: horizontal bone loss at FE level; HBL-max: the maximum distance of HBL in furcation area; VBL-max: the maximum distance of vertical bone loss in furcation area; RT: the length of the root trunk; <sup>a</sup> Twenty-eight sites were not measurable for HBL and HBL-max measurements due to: 1) 'through-and-through' FI in 13 proximal sites, including six mesiopalatal sites and seven distopalatal sites; 2) the two buccal roots were too close to observe the bone level in 1 buccal site in a second maxillary molar; 3) fused roots in 6 sites.

<sup>b</sup> Six sites of fused roots were not measurable for the VBL-max measurement; <sup>c</sup> Nine sites were not measurable for RT because: 1) the cemento-enamel junction could not be identified in three sites; 2) there were fused roots in six sites.

**Table 3** The measurements and ICCs of the two observers.

	Observer 1 <sup>a</sup> (mean ± SD) (mm)	Observer 2 (mean ± SD) (mm)	ICC
HBL (n = 11) <sup>b</sup>	3.01 ± 1.56	2.88 ± 2.34	0.873
HBL-max (n = 11)	4.00 ± 2.52	4.29 ± 2.59	0.947
VBL-max (n = 11)	3.67 ± 1.25	3.96 ± 1.31	0.884
RT (n = 11)	3.07 ± 1.05	2.15 ± 0.86	0.942

<sup>a</sup> The values in the column were recorded as the mean values of double measurements for observer 1.

<sup>b</sup> Eleven sites were measurable for HBL. All four parameters in the 11 sites were measured by observer 2.

**Table 4** The length of the root trunk (RT) on the CBCT.

	Buccal (mean ± SD) (mm)	Distal (mean ± SD) (mm)	Mesial (mean ± SD) (mm)	Total (mean ± SD) (mm)
First molars	2.78 ± 1.06 n = 11	4.53 ± 0.76* n = 10	4.18 ± 1.14* n = 9	3.79 ± 1.25 n = 30
Second molars	3.12 ± 1.42 n = 5	3.41 ± 1.32 n = 2	4.00 ± 0.00 n = 2	3.39 ± 1.21 n = 12
Total	2.89 ± 1.15 n = 16	4.16 ± 1.08* n = 11	4.15 ± 1.02* n = 15	3.67 ± 1.23 n = 42 <sup>a</sup>

\*  $P < 0.05$  (compared with buccal sites); <sup>a</sup> In 63 sites of 21 maxillary molars, 21 sites were not achieved because: 1) the CEJ was obscure in CT images in five sites; 2) there were fused roots in 16 sites.

The RT of second molars was not analysed statistically because of the small sample size.

maxillary molars between CBCT and intra-surgery. However, in their study, the reference point of FE was not described. Instead, the outer root surface was considered as the landmark from where the horizontal bone loss (BL-H) at FE level was estimated. When using the outer root surface as the measuring landmark, an imaginary tangent of the root surface at the level of the FE was applied as the measuring point. Therefore, subjective errors were inevitable. Furthermore, choosing which horizontal plane to do the measurement is very important. However, Qiao et al<sup>15</sup> did not mention these details. In the present study, FE was determined in the Z plane, in which the concave point of the crown first appeared. This is a repeatable method.

Four parameters were proposed to reflect FI on CBCT, including HBL, HBL-max, VBL-max and RT. In past literature, CBCT-measurements for FI was seldom studied except Qiao et al<sup>15</sup>. They also reported four parameters reflecting the extent of FI in CBCT images by BL-V (vertical bone loss), BL-H (bone loss in the horizontal direction), FW (the width of the furcation entrance) and RT. In comparison to their study, HBL and RT were equivalent to their BL-H and RT. We used VBL-max instead of their BL-V. VBL-max described the maximum vertical bone defects which may or may not be in the FE plane. BL-V in their study was the vertical bone loss in the FE plane. Furthermore, in this study it was proposed that HBL-max reflected the maximum HBL of FI. FW was not measured in this study because the plane of the mesiopalatal and distopalatal furcations were not parallel and could not be determined. Qiao et al<sup>15</sup> did not describe the details of FW measurements.

In this study, high reproducibility of the four parameters for FI measured in CBCT images was obtained. The ICCs of the double measurements in the 39 furcation lesions were 0.960 to 0.992. The ICCs of the two observers was also high ranging from 0.873 to 0.947. According to Fleiss's research<sup>16</sup>, values above 0.75 represent excellent reliability; thus, the results indicate that the definition of FE and the measuring planes chosen in the study had high reproducibility, which provides a repeatable method for clinical use.

The parameters developed in the present study could be applied not only to reflect the extent of FI, but also to evaluate the outcome of FI treatment. Conventional assessment of FI treatment includes clinical and radiological methods. Vertical and horizontal attachment level, probing depth and bleeding after probing are the main clinical parameters<sup>17,18</sup>. Re-entry has been considered a 'gold standard' for judging the outcome of furcation therapy<sup>19</sup>. However, the procedure requires second-

ary flap surgery, which has been used in research but is not widely applied in routine clinical work. Periapical radiographs have been used as a radiographic method for evaluating FI treatment. The method was effective in the assessment of mandibular molars<sup>20,21</sup>. However, the application was limited in maxillary molars because in periapical radiograph images furcations are obscured by roots and alveolar bone. Owing to the limitation of two-dimensional images, periapical radiographs could not be used as a quantitative evaluation of HBL in the furcation area. The development of CBCT overcame these shortcomings. In 2001, a case report introduced CBCT when evaluating the outcomes of regenerative therapy for FI<sup>22</sup>. In this paper, the outcomes were assessed by morphological characteristics on the CT image. However, quantitative measurements were lacking. Thus, the parameters and measuring methods for FI in CBCT images developed in the present study provide a non-invasive and effective way to assess treatment outcome.

Furthermore, a few findings in this study may be constructive for clinicians. Firstly, the mean HBL of degree III FI in buccal sites (four in total) was  $4.80 \pm 0.34$  mm, which suggests that if horizontal probing depth in buccal sites is more than 5 mm, the clinician should consider the possibility of a 'through and through' furcation defect. Secondly, the length of the RT obtained from CT data was longer in proximal sites than in buccal sites. This result was similar with the *in vitro* study by Porciuncula et al<sup>23</sup>. This suggested that FIs in proximal sites were associated with more bone loss and a worse prognosis than those in buccal sites because of the longer root trunk. RT was a parameter which was helpful in understanding the location of root separation. It may influence the prognosis and treatment planning. For example, in resective therapeutic procedures, a short root trunk may be a positive factor in prognosis. By contrast, a long root trunk may facilitate the placement of a barrier membrane to achieve full coverage of FI for guided tissue regeneration therapy, thus leading to a better outcome.

One limitation of the present study was that there were no intra-surgical assessments to confirm the results of the CT data. However, direct probing in surgery still has some problems. For example, the direction of probing is usually oblique in the surgery, especially in proximal sites because of the obstruction from neighbouring teeth; the starting point of the FE is not identified objectively during surgery, which influences the reliability and accuracy of the measurements. Meanwhile, more samples are needed in future research.

## Conclusion

In this study, four quantitative parameters were proposed that reflect the extent of maxillary molar FI in CBCT images. The results demonstrate high reproducibility of these parameters. Compared with probing, CBCT provides more details about FI. This repeatable measuring method could help clinicians to apply CBCT when assessing the severity of furcation lesions and when evaluating the outcome of therapy for FI.

## Acknowledgements

The authors would like to thank the staff in the Department of Radiology for their help in collecting CBCT data.

## Conflicts of interest

The authors reported no conflicts of interest related to this study.

## Author contribution

Dr Jie Zhu for carrying out experiments, analysing experimental results and preparing the manuscript. Dr Xiang Ying OuYang for the research design and the manuscript revision.

(Received April 06, 2016; accepted June 06, 2016)

## References

- Hamp SE, Nyman S, Lindhe J. Periodontal treatment of multirrooted teeth. Results after 5 years. *J Clin Periodontol* 1975;2:126–135.
- Eickholz P, Staehle HJ. The reliability of furcation measurements. *J Clin Periodontol* 1994;21:611–614.
- Abbas F, Hart AA, Oosting J, van der Velden U. Effect of training and probing force on the reproducibility of pocket depth measurements. *J Periodontol Res* 1982;17:226–234.
- Fuhrmann RA, Buecker A, Diedrich PR. Furcation involvement: comparison of dental radiographs and HR-CT-slices in human specimens. *J Periodontol Res* 1997;32:409–418.
- Topoll HH, Streletz E, Hucke HP, Lange DE. Furcation diagnosis-comparison of orthopantomography, full mouth X-ray series, and intraoperative finding [In German]. *Dtsch Zahnarztl Z* 1988;43:705–708.
- Hardekopf JD, Dunlap RM, Ahl DR, Pelleu GB Jr. The “furcation arrow”. A reliable radiographic image? *J Periodontol* 1987;58:258–261.
- Braun X, Ritter L, Jervøe-Storm PM, Frentzen M. Diagnostic accuracy of CBCT for periodontal lesions. *Clin Oral Invest* 2014;18:1229–1236.
- Corpas Ldos S, Jacobs R, Quirynen M, Huang Y, Naert I, Duyck J. Peri-implant bone tissue assessment by comparing the outcome of intra-oral radiograph and cone beam computed tomography analyses to the histological standard. *Clin Oral Implants Res* 2011;22:492–499.
- Fienitz T, Schwarz F, Ritter L, Dreiseidler T, Becker J, Rothamel D. Accuracy of cone beam computed tomography in assessing peri-implant bone defect regeneration: a histologically controlled study in dogs. *Clin Oral Implants Res* 2012;23:882–887.
- Jervøe-Storm PM, Hagner M, Neugebauer J, et al. Comparison of cone-beam computerized tomography and intraoral radiographs for determination of the periodontal ligament in a variable phantom. *Oral Surg Oral Med Oral Pathol Oral Radiol Endod* 2010;109:e95–e101.
- Misch KA, Yi ES, Sarment DP. Accuracy of cone beam computed tomography for periodontal defect measurements. *J Periodontol* 2006;77:1261–1266.
- Nikneshan S, Aval SH, Bakhshalian N, Shahab S, Mohammadpour M, Sarikhani S. Accuracy of linear measurement using cone-beam computed tomography at different reconstruction angles. *Imaging Sci Dent* 2014;44:257–262.
- Glickman I. *Clinical Periodontology*. Philadelphia: W. B. Saunders, 1958.
- Zhong JS, Ou-Yang XY, Liu DG, Cao CF. Evaluation of the in vitro quantitative measurement of II degree furcation involvements in mandibular molars by cone-beam computed tomography [In Chinese]. *Beijing Da Xue Xue Bao* 2010;42:41–45.
- Qiao J, Wang S, Duan J, et al. The accuracy of cone-beam computed tomography in assessing maxillary molar furcation involvement. *J Clin Periodontol* 2014;41:269–274.
- Fleiss JL, Chilton NW. The measurement of interexaminer agreement on periodontal disease. *J Periodontol Res* 1983;18:601–606.
- Hoffmann T, Richter S, Meyle J, et al. A randomized clinical multicentre trial comparing enamel matrix derivative and membrane treatment of buccal class II furcation involvement in mandibular molars. Part III: patient factors and treatment outcome. *J Clin Periodontol* 2006;33:575–583.
- McClain PK, Schallhorn RG. Long-term assessment of combined osseous composite grafting, root conditioning, and guided tissue regeneration. *Int J Periodontics Restorator Dent* 1993;13:9–27.
- Jepsen S, Heinz B, Jepsen K, et al. A randomized clinical trial comparing enamel matrix derivative and membrane treatment of buccal Class II furcation involvement in mandibular molars. Part I: Study design and results for primary outcomes. *J Periodontol* 2004;75:1150–1160.
- Jenabian N, Haghanifar S, Maboudi A, Bijani A. Clinical and radiographic evaluation of Bio-Gen with biocollagen compared with Bio-Gen with connective tissue in the treatment of class II furcation defects: a randomized clinical trial. *J Appl Oral Sci* 2013;21:422–429.
- Horwitz J, Machtei EE, Reitmeir P, Holle R, Kim TS, Eickholz P. Radiographic parameters as prognostic indicators for healing of class II furcation defects. *J Clin Periodontol* 2004;31:105–111.
- Ito K, Yoshinuma N, Goke E, Arai Y, Shinoda K. Clinical application of a new compact computed tomography system for evaluating the outcome of regenerative therapy: a case report. *J Periodontol* 2001;72:696–702.
- Porciúncula HF, Zuza EP, da Porciúncula MM, de Toledo BE, Mendes AJ. Root trunk height as a risk factor for periodontal furcation involvement in maxillary first molars: an in vitro study. *J Int Acad Periodontol* 2007;9:89–95.